

Acute Dental Emergencies In Emergency Medicine

May 2003
Volume 5, Number 5

"What do you mean, you don't have a dentist in the emergency department?"

"Go ahead, Doc—just pull it."

"I called my dentist's office but got no answer. He pulled my tooth this morning and now it's bleeding like crazy. Oh, yeah—I'm on Coumadin!"

SOUND familiar? Complaints pertaining to teeth are common, and patients frequently present to the ED for initial care. Many patients realize that definitive care must be provided by a dentist or oral surgeon, but either pain, trauma, inability to contact their dentist, or the lack of financial resources leads patients to our EDs.¹ While treating dental emergencies in the ED can be challenging and frustrating, it can also be immensely satisfying. There is no more appreciative patient than one relieved of severe dental pain. Many emergency physicians are unable to recognize and treat acute dental problems because of a lack of specific training, yet proper initial care will limit morbidity such as tooth loss, pain, infection, and, potentially, craniofacial abnormality. Moreover, while "dental patients" are often triaged as non-emergent, some of these patients deserve ICU-level care from the moment that they come into the ED.

Critical Appraisal Of The Literature

The literature regarding the treatment of dental emergencies in the ED is mostly extrapolated from other specialties. There are no ED-based outcome studies or randomized, controlled studies addressing specific treatment modalities for fractured teeth, avulsed teeth, infected teeth, odontalgia and nerve block anesthesia, or alveolar osteitis (dry sockets). Interestingly, prospective outcome data with regard to traumatized teeth are also scarce in the dental literature. There are no universally accepted guidelines regarding the ED treatment of acutely injured or infected teeth. Several studies are currently under way that address the treatment of dental pain with dental blocks in the ED, but none have yet been published.

Author

Kip Benko, MD, FACEP

Clinical Instructor in Emergency Medicine,
University of Pittsburgh School of Medicine;
Attending Physician, Mercy Hospital of Pittsburgh,
Pittsburgh, PA.

Peer Reviewers

Marianne C. Burke, MD

Emergency Medicine Consultants, Los Angeles, CA.

Charles Stewart, MD, FACEP

Colorado Springs, CO.

CME Objectives

Upon completing this article, you should be able to:

1. describe the structure, classification, and identification of primary and permanent teeth;
2. discuss appropriate historical questions and physical examination techniques for both traumatic and non-traumatic dental emergencies;
3. describe appropriate anesthesia for patients with dental emergencies, including dental block techniques most frequently required in the ED;
4. describe the ED treatment of traumatic and non-traumatic dental emergencies; and
5. describe appropriate disposition of patients with different types of dental emergencies, including indications for referral.

Date of original release: May 1, 2003.

Date of most recent review: April 9, 2003.

See "Physician CME Information" on back page.

Editor-in-Chief

Stephen A. Colucciello, MD, FACEP, Assistant Chair, Department of Emergency Medicine, Carolinas Medical Center, Charlotte, NC; Associate Clinical Professor, Department of Emergency Medicine, University of North Carolina at Chapel Hill, Chapel Hill, NC.

Associate Editor

Andy Jagoda, MD, FACEP, Vice-Chair of Academic Affairs, Department of Emergency Medicine; Residency Program Director; Director, International Studies Program, Mount Sinai School of Medicine, New York, NY.

Editorial Board

Judith C. Brillman, MD, Residency Director, Associate Professor, Department of Emergency Medicine, The University of

New Mexico Health Sciences Center School of Medicine, Albuquerque, NM.

W. Richard Bukata, MD, Clinical Professor, Emergency Medicine, Los Angeles County/USC Medical Center, Los Angeles, CA; Medical Director, Emergency Department, San Gabriel Valley Medical Center, San Gabriel, CA.

Francis M. Fesmire, MD, FACEP, Director, Heart-Stroke Center, Erlanger Medical Center; Assistant Professor of Medicine, UT College of Medicine, Chattanooga, TN.

Valerio Gai, MD, Professor and Chair, Department of Emergency Medicine, University of Turin, Italy.

Michael J. Gerardi, MD, FACEP, Clinical Assistant Professor, Medicine, University of Medicine and Dentistry of New Jersey; Director, Pediatric Emergency Medicine, Children's Medical Center, Atlantic Health System;

Vice-Chairman, Department of Emergency Medicine, Morristown Memorial Hospital.

Michael A. Gibbs, MD, FACEP, Chief, Department of Emergency Medicine, Maine Medical Center, Portland, ME.

Gregory L. Henry, MD, FACEP, CEO, Medical Practice Risk Assessment, Inc., Ann Arbor, MI; Clinical Professor, Department of Emergency Medicine, University of Michigan Medical School, Ann Arbor, MI; President, American Physicians Assurance Society, Ltd., Bridgetown, Barbados, West Indies; Past President, ACEP.

Jerome R. Hoffman, MA, MD, FACEP, Professor of Medicine/Emergency Medicine, UCLA School of Medicine; Attending Physician, UCLA Emergency Medicine Center; Co-Director, The Doctoring Program, UCLA School of Medicine, Los Angeles, CA.

Francis P. Kohrs, MD, MSPH, Associate Professor and Chief of the Division of Family Medicine, Mount Sinai School of Medicine, New York, NY.

John A. Marx, MD, Chair and Chief, Department of Emergency Medicine, Carolinas Medical Center, Charlotte, NC; Clinical Professor, Department of Emergency Medicine, University of North Carolina at Chapel Hill, Chapel Hill, NC.

Michael S. Radeos, MD, MPH, Attending Physician, Department of Emergency Medicine, Lincoln Medical and Mental Health Center, Bronx, NY; Assistant Professor in Emergency Medicine, Weill College of Medicine, Cornell University, New York, NY.

Steven G. Rothrock, MD, FACEP, FAAP, Associate Professor of Emergency Medicine, University of Florida; Orlando Regional Medical Center; Medical Director of Orange County Emergency

Medical Service, Orlando, FL.

Alfred Sacchetti, MD, FACEP, Research Director, Our Lady of Lourdes Medical Center, Camden, NJ; Assistant Clinical Professor of Emergency Medicine, Thomas Jefferson University, Philadelphia, PA.

Corey M. Slovis, MD, FACP, FACEP, Professor of Emergency Medicine and Chairman, Department of Emergency Medicine, Vanderbilt University Medical Center; Medical Director, Metro Nashville EMS, Nashville, TN.

Mark Smith, MD, Chairman, Department of Emergency Medicine, Washington Hospital Center, Washington, DC.

Charles Stewart, MD, FACEP, Colorado Springs, CO.

Thomas E. Terrndrup, MD, Professor and Chair, Department of Emergency Medicine, University of Alabama at Birmingham, Birmingham, AL.

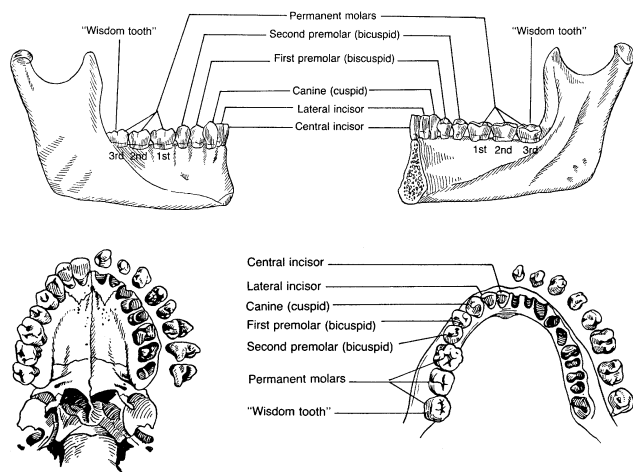
Although adequate treatment guidelines can be derived from other specialty literature, it must be remembered that because dentists and maxillofacial/oral surgeons often provide definitive care, their recommended modalities are not necessarily appropriate for the ED. Several textbooks make treatment recommendations based on dental literature that are impractical or not appropriate for emergency physicians unskilled in those techniques. There are several reviews in the emergency medicine literature that present guidelines for emergency physicians, but these are not based on ED studies.²⁻⁴ The application of principles based on the dental literature to an ED population requires a working knowledge of basic dental anatomy and physiology as well as an understanding of the medications, medicaments, anesthetics, glues, pastes, and bonding/splinting materials used in the dental professional's office.

Epidemiology, Etiology, And Pathophysiology

The incidence of dental complaints presenting to the ED appears to be rising, ranging from 0.4% to 10.5%, which may reflect the increasing use of EDs as primary care facilities.^{1,5} Injuries in the younger population are often related to falls or accidents, whereas those in the older age group are often secondary to falls, assaults, or motor vehicle accidents.^{1,3} Dental trauma presenting to EDs usually involves the permanent dentition and most commonly the anterior teeth. Dentoalveolar injuries in adults are also found in association with fractures of the mandible and face. Patients with combined mandibular body and condyle fractures are more likely to have related tooth injury than either isolated body or condyle fractures alone.³

A thorough understanding of the dental anatomic subunits allows not only proper ED treatment, but also a more concise and directed discussion with dental

Figure 1. Classification of teeth.



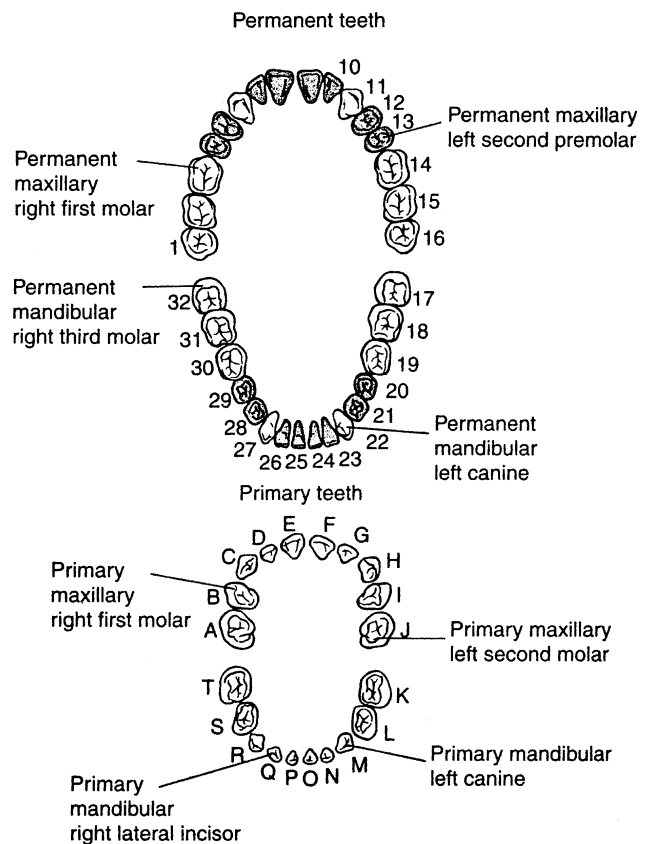
Used with permission from: Roberts JR, Hedges JR, eds. *Clinical Procedures in Emergency Medicine*. 2nd ed. Philadelphia: W.B. Saunders; 1991:1047. Figure 87-3.

consultants. Simply saying "There's a broken middle upper tooth that's bleeding" is not very informative to your dental colleague.

The adult dentition consists of 32 teeth, of which there are four types: eight incisors, four canines, eight premolars, and 12 molars. From the midline to the back of the mouth there is a central incisor, lateral incisor, canine, two premolars (bicuspid), and the three molars, the last of which is the troublesome wisdom tooth. (See Figure 1.) The adult teeth are numbered from 1 to 32, with the #1 tooth being the right upper third molar and the #16 tooth being the left upper third molar. The left lower third molar is #17, and the #32 tooth is the right lower third molar. (See Figure 2.) It is more important that the emergency physician be able to describe the tooth involved rather than remembering which number belongs to which tooth. Therefore, simply describe the location and type of the problem tooth (for example, "the upper left second premolar" or "the lower right canine").

The primary dentition ("baby teeth"), likewise, is best described by determining which tooth is involved. The earliest teeth to erupt in a child are the central incisors, usually at 4-8 months. The child usually has a full complement of primary teeth by the end of the third year of life. The primary dentition is designated as

Figure 2. Identification of teeth.



Used with permission from: Tintinalli JE, Kelen GD, Stapczynski JS, eds. *Emergency Medicine: A Comprehensive Study Guide*. 5th ed. New York: McGraw Hill; 2000. Figure 234-2.

follows: The right maxillary second molar is designated as A, and the left maxillary second molar is designated as J. The left mandibular second molar is designated as K, and the right mandibular second molar is designated as T. The teeth in between are lettered accordingly (See Table 1.) Children often have teeth that are missing or incompletely erupted; therefore, it is best to use the name of the tooth instead of letters when communicating with a specialist. The permanent teeth usually start replacing the primary teeth at approximately 5 years of age, and this process begins with the incisors.

A tooth consists of the central pulp, the dentin, and the enamel. (See Figure 3.) The pulp contains the neurovascular supply of the tooth that carries nutrients to the dentin, a microporous substance that consists of a system of microtubules. The dentin makes up the majority of the tooth and also serves to cushion the tooth during mastication. The enamel is the white visible portion of the tooth and is the hardest part of the body. The tooth may also be described in terms of the crown (coronal portion) or the root. The crown is that portion covered in enamel, and the root is the part that serves to anchor the tooth in the alveolar bone.

The following descriptive terminology is used for the different anatomic surfaces of the tooth and is helpful when describing a specific tooth injury to a consultant or colleague.

- **Facial:** that part of the tooth that you see when somebody smiles. This is a general term and is applicable to all teeth. It is sufficient to use when describing an injury, but the following is more specific and precise:
 - **Labial:** refers to the facial surface of the incisors and canines.
 - **Buccal:** refers to the facial surface of the premolars and molars.
- **Oral:** that part of the tooth that faces the tongue or

the palate. This is also a general term and is applicable to all teeth, but the following is more precise:

- **Lingual:** toward the tongue, the oral surface of the mandibular teeth.
- **Palatal:** toward the palate, the oral surface of the maxillary teeth.
- **Approximal/ Interproximal:** the contacting surfaces between two adjacent teeth.
 - **Mesial:** the interproximal surface facing anteriorly or closest to the midline.
 - **Distal:** the interproximal surface facing posteriorly or away from the midline.
- **Occlusal:** the biting or chewing surface of the premolars or molars.
- **Incisal:** the biting or chewing surface of the incisors and canines.
- **Apical:** toward the root of the tooth.
- **Coronal:** toward the crown or the biting surface of the tooth.

The attachment apparatus, also known as the periodontium, consists of two major subunits and is necessary for maintaining the integrity of the normal dentoalveolar unit.

- The gingival subunit consists of the junctional epithelium and the gingival tissue.
- The periodontal subunit includes the periodontal ligament, alveolar bone, and the cementum of the root of the tooth.

Infections and certain disease states of the gingiva weaken the attachment apparatus and can result in tooth

Table 1. Dentition and age at eruption.

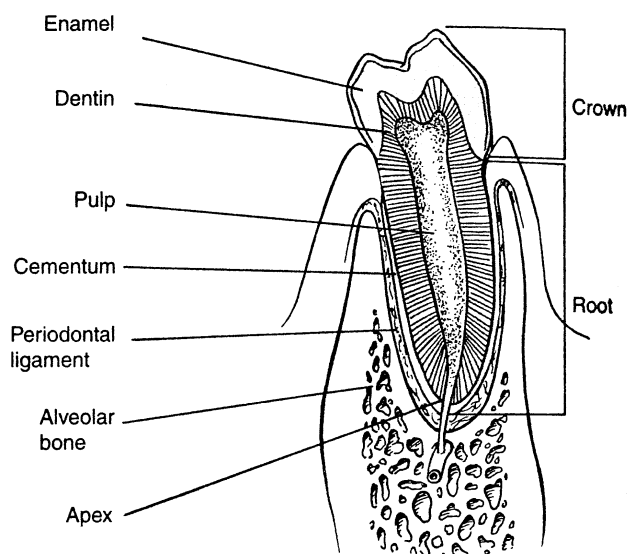
Primary (baby) teeth

Name of tooth	Appearance in the mouth
Central incisor	4-14 months
Lateral incisor	8-18 months
Canine tooth	14-24 months
First molar	10-20 months
Second molar	20-36 months

Permanent (adult) teeth

Name of tooth	Appearance in the mouth
Central incisor	5-9 years
Lateral incisors	6-10 years
Canine tooth	8.5-14 years
First premolar (bicuspid)	9-14 years
Second premolar (bicuspid)	10-15 years
First molar (6-year molar)	5-9 years
Second molar (12-year molar)	10-15 years
Third molar (wisdom tooth)	17-25 years

Figure 3. The dental anatomic unit and attachment apparatus.



Used with permission from: Tintinalli JE, Kelen GD, Stapczynski JS, eds. *Emergency Medicine: A Comprehensive Study Guide*. 5th ed. New York: McGraw Hill; 2000. Figure 234-3.

loss. Likewise, avulsed teeth, even if replaced in a timely manner, often will not reattach if the gingival subunit is weakened by poor hygiene or disease.

Differential Diagnosis

The differential diagnosis is fairly straightforward when dealing with dental trauma. The primary considerations to take into account are whether or not the existent trauma could potentially cause airway compromise. Associated injuries include mandibular, maxillary, or alveolar ridge fractures that may leave the tongue unsupported or the midface unstable. Each scenario may lead to difficulty when performing intubation or ventilating the patient with a bag-valve mask. Mucosal or tongue lacerations may cause bleeding severe enough to compromise the airway. It is also important to evaluate for associated injuries, such as closed head or cervical spine injuries.

Trauma to the teeth usually consists of fracture, subluxation (loose, nondisplaced teeth), luxation (displaced teeth), or complete avulsion. The diagnosis is primarily determined by a meticulous physical examination, accounting for each tooth and portion of tooth. Radiography usually serves a confirmatory role.

Non-traumatic dental emergencies usually result from poor oral hygiene, recent instrumentation, or infection. Uncomplicated tooth pain (odontalgia) usually reflects pulpitis, and further diagnostic studies are not required in the ED. The other consideration is periodontal or pulpal infection or abscess. Referred pain from the sinuses or the temporomandibular joint also must be considered, especially when non-localizable tooth pain exists. (See Table 2.) Dry sockets (alveolar osteitis), hematomas, or hemorrhage may present to the ED after instrumentation or extraction.

While pulpitis represents one end of the spectrum, deep space infections represent the other. These rapidly spreading infections can be life-threatening, especially if they dissect into the chest, causing mediastinitis.⁶ The exact location of the deep space infection is not critically important, but rapid initiation of treatment is crucial in preventing airway compromise. The urgency of the intervention, of course, depends on the severity of presentation; a patient with severe trismus, stridor, and drooling may require an emergent surgical airway.

Prehospital Care

Prehospital care should focus primarily on protection of the airway and secondarily on preservation of dentition. EMS providers as well as patients and bystanders can significantly alter outcomes with regard to the preservation of avulsed teeth. Loose or displaced teeth should not be manipulated unless airway intervention is required. Hemorrhage control can be initiated with gauze and direct pressure if the site of hemorrhage is visible. Medics should evaluate the risk of gauze aspiration if the patient is immobilized on a backboard or is intoxicated.

Significant airway hemorrhage or swelling may cause complete airway obstruction if the patient is placed supine. The position of choice in these patients is the upright sitting position. If cervical spine injury is a major concern and the patient must be placed in a supine position, airway equipment including suction must be readily available, and personnel must be prepared to place a definitive airway. In most cases of isolated dental trauma, expeditious transport is all that is required. If there are avulsed teeth, the patient and/or EMS providers should be instructed that:

- The tooth should be handled by the crown only. Handling the tooth by the root can damage the periodontal ligament.
- The tooth should not be replaced if the root is

Table 2. The differential diagnosis of orofacial pain.

Odontogenic origin	Mandible/maxilla fracture Mucosa/tongue lacerations
Dental caries	
Reversible pulpitis	
Irreversible pulpitis	
Pulpal necrosis and abscess	Infection
Tooth eruption	Oral candidiasis
Pericoronitis	Herpes simplex, types 1 and 2
Postrestorative pain	Varicella-zoster, primary and secondary
Postextraction discomfort	Herpangina
Postextraction alveolar osteitis	Hand, foot, and mouth disease
Bruxism	Sexually transmitted diseases
Cervical erosion	Mycobacterial infections
Deep space odontogenic infection	Mumps
Deep space hematoma	
Alveolar osteitis	Malignancies
Periapical abscess	Squamous cell carcinoma
Dentoalveolar abscess	Kaposi's sarcoma
Oral hemorrhage	Lymphoma
	Leukemia
Periodontal pathology	Graft-versus-host disease
Gingivitis	Melanoma
Periodontal disease	
Periodontal abscess	Other etiologies
Acute necrotizing gingivostomatitis	Cranial neuralgias
	Stomatitis and mucositis: uremia, vitamin deficiency, other
Orofacial trauma	Erythema migrans
Dental fractures: Subtle enamel cracks, Ellis fractures	Pyogenic granuloma
Dental subluxation, luxation, intrusion, and avulsion	Ulcerative disease: Lichen planus, cicatricial pemphigoid, pemphigus vulgaris, erythema multiforme
Facial fractures	Crohn's disease
Alveolar ridge fractures	Behçet's syndrome
Soft-tissue lacerations	
Traumatic ulcers	

Adapted from: Tintinalli JE, Kelen GD, Stapczynski JS, eds. *Emergency Medicine: A Comprehensive Study Guide*. 5th ed. New York: McGraw-Hill; 2000.

fractured or if there is significant maxillofacial trauma such as an alveolar ridge fracture.

- If the tooth can be replaced in the prehospital setting, the root should be gently *rinsed* off first to remove any debris (preferably with saline). *The root should not be wiped off as this removes the periodontal ligament.*^{7,8}
- If the tooth cannot be successfully reimplanted in the field, it should be placed in a transport medium as outlined in the “Treatment” section later in this article. Transporting the tooth in the oral cavity such as in the cheek may risk aspiration. This location is also not ideal for keeping the periodontal ligament alive because of the bacterial flora and low osmolality of the saliva.^{4,9}

ED Evaluation

History

The evaluation of dental complaints in the ED consists of a focused history and physical examination. Important historical information with regard to traumatic injuries includes the following:

1. When did the incident occur? The timing of the incident is critically important when evaluating avulsed *permanent* teeth, as the decision to reimplant the tooth is largely based on the duration that the tooth was avulsed.
2. Were any teeth found at the scene?
3. Did the patient experience any coughing after the injury? This may suggest aspiration of a tooth.
4. Has the patient been drinking alcohol or using other sedatives (including recreational drugs)? This may increase the possibility of aspiration.
5. Was a loss of consciousness associated with the injury?
6. Does the patient complain of pain? Do the teeth feel as if they are meeting normally? Is the pain associated with occlusion? Mandibular fractures are often worse with moving the jaw, and patients will often complain that their teeth are not meeting normally. Pain from temporomandibular joint injuries is often referred to the ear. Fractured teeth hurt worse with the inspiration of air or contact with cold substances.
7. Did the patient apply any substance to the teeth to decrease the pain? Over-the-counter anesthetics and topical analgesics can cause sterile abscesses if applied onto the pulp or dentin.¹⁰
8. Does the patient have a history of dental work involving the traumatized tooth?
9. Is the tooth a primary or secondary tooth? Traumatized primary teeth are managed differently than permanent teeth.
10. Does the patient have a history of bleeding disorders or allergies to medicines?

The following additional information should be obtained in cases of nontraumatic dental complaints:

1. Has there been any recent dental work or instrumentation performed? Dry sockets, for example, occur

after a tooth has been extracted.

2. Has the patient had a history of poor dentition or multiple caries? Has he or she had routine preventative dental care, and when was the most recent visit to the dentist?
3. Is the patient having difficulty opening his or her mouth or swallowing? Has there been a change in his or her voice? Is there any shortness of breath? Such complaints would raise the concern for deep space infections.
4. Is the patient immunocompromised in any way? Deep space infections can spread rapidly and progress to the mediastinum or the cavernous sinus in immunocompromised patients.
5. Is the patient taking aspirin, warfarin, or other anticoagulants? Is there a history of bleeding disorders, heavy menstrual periods, bleeding into joints, or heavy bleeding after dental procedures in the past?
6. What over-the-counter preparations has the patient been using?
7. What has the time course of the symptoms been? Has it been rapid or insidious? Have there been symptoms consistent with severe infection, such as fevers, chills, or vomiting?
8. Does the patient have drug allergies?
9. Does the patient have a history of rheumatic fever or valvular disease such as mitral valve prolapse?¹¹ Does the patient have implanted devices such as artificial joints, valves, or shunts? These may predispose to endocarditis or infection of an implant.

Physical Examination

The physical examination needs to be meticulous. Injuries to the dentition are easily missed because of more impressive traumatic findings or a casual examination. Likewise, the nooks and crannies of the mouth can hide fairly significant-sized abscesses and injuries.

The examination should begin with observation and simply talking to the patient. Look for airway involvement, voice change, muffling, drooling, etc. External inspection is important as many injuries such as mandibular dislocations and fractures are diagnosed by noting asymmetry, deformity, or swelling of the face. Abscesses or deep space infections will often result in swelling over the involved space. Visualize the face from multiple angles to note subtle asymmetries. The opening and closing of the mouth should be smooth and complete, with no limitations or hesitation. Erythema, warmth, or drainage is indicative of abscess, cellulitis, or hematoma formation. Muffling of the voice provides clues to impending airway compromise. Palpate the face for tenderness, crepitus, or step-offs. The entire mid-face and mandible should be palpated, with particular attention paid to the maxilla, zygomas, and the mandibular condyles and coronoid processes. The area of the temporomandibular joints should be palpated carefully throughout the range of motion. There should not be any pops, clicks, or pain.

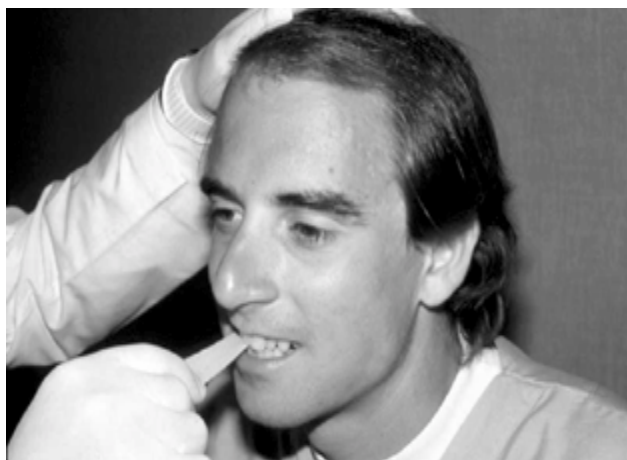Palpate the neck with special attention to the area beneath the mandibular body and assess for swelling or tenderness. The oral cavity should be inspected for any bleeding, swelling, tenderness, step-offs, or lacerations. Each tooth should be accounted for. A tongue blade should be used to visualize the entire mucobuccal fold region. Palpate the cheek and the floor of the mouth with a gloved hand. Each tooth should be percussed with a tongue blade for sensitivity and palpated with fingers or tongue blades for mobility. Blood in the gingival crevice (the area where the gingiva contacts the enamel) suggests a traumatized tooth or even a fractured jaw. The teeth should meet symmetrically and evenly when biting and the patient should be able to exert firm pressure on a tongue blade with his or her molars. The inability to crack a tongue blade bilaterally when it is twisted between the molars (tongue-blade test) suggests a mandibular fracture.¹² (See Figure 4.)

Diagnostic Studies

The routine evaluation and treatment of most dental emergencies can be performed without radiographic studies or laboratory evaluation. Unlike definitive treatment in the dentist's or oral surgeon's office, the ED treatment of tooth fractures or alveolar ridge fractures is usually not changed by information gained from x-rays. Radiographs can be helpful, however, if a tooth fragment is missing and thought to be aspirated or lodged in the lip or buccal mucosa. Likewise, intruded teeth are not always apparent, and x-rays can help distinguish between an intruded and an avulsed tooth.

A Panorex view and a Townes view are probably the most useful and cost-effective views to obtain when evaluating mandibular trauma in the ED.^{13,14} The Panorex (panoramic radiograph) of the mandible shows the mandible in its entirety and demonstrates fractures in all regions, including the symphysis.¹³ However, the Panorex can rarely miss overriding anterior fractures.¹⁵ An occlusal view or CT is indicated if this is likely. The Townes view allows slightly better visualization of the condyles and should be used if the condylar regions

Figure 4. Tongue blade test.



cannot be visualized adequately with panoramic radiography.¹³ Coronal CT scanning is more definitive and is often used in preoperative evaluation, but it is usually unnecessary for diagnostic purposes in the ED. CT should be obtained if multiple facial fractures are suspected or if the initial evaluation of mandibular trauma is equivocal and the clinical suspicion is high.^{13,16} If the patient is immobilized, in a cervical collar, or unable to sit still in a Panorex machine, plain mandibular films or CT scanning should be performed. Mandibular films have the disadvantage of not visualizing the symphysis well, and occlusal films may be required to visualize this part of the mandible.

Simple abscesses or infections are best treated by antibiotics or incision and drainage (in the case of a periapical abscess). Although Panorex views can identify sizable periapical abscesses, their routine use in the ED is not warranted in such cases, as the treatment and disposition of the patient will not change.¹⁰ Routine bloodwork, such as blood counts and chemistries, is not useful for the majority of patients and should be considered on an individual basis. Bleeding times and coagulation profiles are unnecessary in routine cases of post-extraction or traumatic intraoral bleeding, but they should be considered if the patient is anticoagulated or the history is compatible with a bleeding disorder.

Anesthesia

Local Anesthesia

Severe tooth pain (odontalgia), as anyone who has had it knows, can be debilitating. Often, the quickest relief is found in the ED.

The ability to perform dental blocks is an invaluable and rewarding skill. Although a complete discussion of all the dental blocks and available anesthetics is beyond the scope of this text, the commonly used anesthetics and the finer points of performing a supraperiosteal infiltration (an apical or tooth block) are presented. The inferior alveolar block is also discussed. Standard emergency medicine procedural texts contain complete information on dental blocks, anesthetics, and regional oral anesthesia.^{17,18}

Topical Anesthetics

Topical anesthetics can be used to provide pain relief from injections, infections, inflammatory conditions, ulcerations, and wounds. While topical preparations decrease the pain of dental block injection, they do not have much effect on the hard palate.¹⁸ Topical preparations come in liquids, sprays, or viscous gels. Benzocaine 6%-20%, an ester, is one of the most commonly used topical dental anesthetics because of its rapid onset (30 seconds), brief duration (5-15 minutes), and lack of systemic absorption. Lidocaine 2%-5%, an amide, also is available in sprays, gels, viscous solutions, and liquids. Gels are more effective on the mucosa than the liquid forms.¹⁸ Likewise, the higher concentrations are much more effective than the lower concentrations.¹⁸ Dental

offices usually stock the higher concentrations of lidocaine (5%) and benzocaine (20%).

The gel-form topical anesthetics are usually applied with a cotton-tipped applicator onto the mucosa over the point of injection. Benzocaine requires a few minutes for maximal effect. Lidocaine requires several more minutes than benzocaine until maximal anesthesia is obtained.

Injectable Anesthetics

The choice of injectable anesthetic depends on a number of factors, including duration of action, side effects, patient allergies, and whether a vasoconstrictor is needed. Table 3 shows the average durations of action of common local anesthetic preparations. The use of a longer-lasting anesthetic, such as bupivacaine, is recommended for painful conditions in which definitive care will most likely be provided in the dentist's office, such as pulpitis, periapical abscess, or a fractured tooth. Bupivacaine with epinephrine provides 6-8 hours of complete anesthesia and several more hours of partial anesthesia.¹⁸ A shorter-acting anesthetic is more appropriate when a procedure such as laceration repair needs to be undertaken, such as a buccal mucosa or tongue laceration. Both bupivacaine and lidocaine (with and without a vasoconstrictor) are available as carpules, which are used in ringed syringe injectors. These injectors have a ring in which the thumb is placed to provide greater control over the procedure.

The use of ringed syringe aspirators is recommended when performing any intraoral injections for a number of reasons—the foremost being that they afford more one-handed maneuverability than a standard medical plunger as well as an increased ability to aspirate. The most common complications and side effects of intraoral injections can be minimized by avoiding intravascular injection.¹⁸ Ringed syringe aspirators allow aspiration before injection. Both reusable and disposable ringed syringes are available.

Supraperiosteal Infiltration

The supraperiosteal infiltration is ideally suited for anesthesia of a single tooth or circumscribed portion of the mandible or maxilla. A slightly larger dose of anesthetic should be used when performing a supraperiosteal infiltration on mandibular teeth secondary to the density and increased thickness of the mandible. The discussion that follows applies to all individual teeth. To obtain maximal effect, the needle tip should overlie the apex of the tooth being anesthetized. The amount of anesthetic will vary with the experience of the clinician and the location of the tooth (mandibular teeth require more, as do posterior teeth), but generally within 1.0-2.5 cc is adequate.

The topical anesthetic is applied to the mucobuccal fold in the general area where the injection will take place. After the topical sets up, the area of injection should be wiped dry. The patient's lip should be retracted by the clinician's non-injecting hand. The needle is inserted near the greatest concavity of the mucobuccal fold and is directed toward the apex of the tooth, usually at a depth of 3-4 mm. If the bone is contacted, the needle should be slightly withdrawn in order to prevent the anesthetic from being inadvertently injected beneath the periosteum. The local anesthetic is injected after a negative aspirate is obtained.

Inferior Alveolar Block

The inferior alveolar nerve block provides pain control from the retromolar region of the mandible to the midline. It is ideal for all of the mandibular teeth, lower lip, and chin on one side. The landmarks that are important are the retromolar fossa and the anterior border of the ramus of the mandible (coronoid notch) as well as the contralateral premolars.

The block is performed by placing the non-injecting thumb into the mouth and retracting the mucosa. The thumb itself should be placed up against the anterior

Table 3. Dental anesthesia: Duration of action in minutes.

Preparation	<u>Maxillary infiltration</u>		<u>Inferior alveolar block</u>	
	Pulpal tissue	Soft tissue	Pulpal tissue	Soft tissue
0.4% Propoxycaine HCl; 2% prilocaine HCl; 1:20,000 levonordefrin or 1:30,000 norepinephrine	40	145	60	175
2% Lidocaine HCl; 1:100,000 or 1:50,000 epinephrine	60	170	85	190
2% Mepivacaine HCl; 1:20,000 levonordefrin	50	130	75	185
3% Mepivacaine HCl	25	90	40	165
4% Prilocaine HCl	20	105	55	190
4% Prilocaine HCl; 1:200,000 epinephrine	40	140	60	220
0.5% Bupivacaine HCl; 1:200,000 epinephrine	40	340	240	440
1.5% Etidocaine HCl; 1:200,000 epinephrine	30	280	240	470
4% Articaine HCl; 1:200,000 or 1:100,000 epinephrine	60	170	90	220

border of the ramus of the mandible in the coronoid notch. (See Figure 5.) The injection point should be approached from the opposite premolars, and the needle is placed approximately 1.0-1.5 cm posteriorly to the midline of the thumbnail. The needle tip is advanced until the mandibular bone is contacted, usually 1.5-2.0 cm. Aspiration is performed to rule out intravascular injection, and the anesthetic is delivered. Usually, 1.0-3.0 cc of anesthetic is adequate.

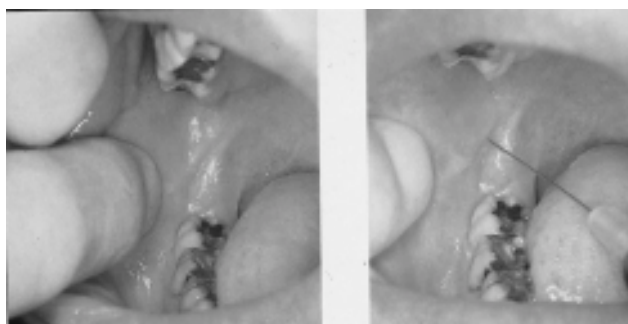
Treatment

Dental Fractures

Injury to maxillary central incisors accounts for between 70% and 80% of all fractured teeth.¹⁹ Although not life-threatening, the morbidity associated with dental fractures can be significant, including failure to complete eruption, abscess, loss of space in the dental arch, color change of the tooth, ankylosis, abnormal exfoliation, and root resorption.

Some general principles apply to the ED evaluation and management of dental trauma.

Figure 5. Inferior alveolar block.



1. *Identify all fracture fragments and mobile teeth and note if a mandible fracture is open or closed.* Radiographs should be taken if there is intrusion of fragments into the mucosa or alveolar bone. Obtain a chest x-ray if a patient with a missing tooth has pulmonary complaints after the injury, such as cough or shortness of breath. It must be remembered, however, that patients who may present with avulsion of a tooth may not recall coughing because of intoxication or other trauma.
2. *The dentition is much more easily manipulated if the patient is not in significant discomfort.* Tooth infiltration and dental block anesthesia should be part of the emergency physician's armamentarium. Narcotic and nonnarcotic alternatives, while helpful after treatment is completed, do not usually offer the patient the comfort required to perform most dental manipulations. If the procedure to be performed is simple, such as applying some glue to a lost cap or filling, a dental block is unnecessary and oral alternatives offer a more reasonable choice.
3. *Avoid topical tooth remedies and analgesics, both over-the-counter and prescribed, as their use can lead to the development of sterile abscesses and soft-tissue irritation.*¹⁰
4. *Administer tetanus vaccination if indicated.* ED management of fractured teeth depends on the extent of fracture with regard to the pulp, the degree of development of the apex of the tooth, and the age of the patient. There are many ways to classify dentoalveolar injuries and, in particular, tooth fractures.²⁰ The Ellis classification system is one often cited in the emergency medicine literature;²¹ however, many dentists and maxillofacial surgeons do not use this nomenclature. The most easily under-

Cost- and Time-Saving Strategies For Dental Emergencies

1. Radiography for routine ED evaluation of dental pain should be discouraged, as the most useful x-rays (bite-wing x-rays) usually cannot be obtained, and rarely would they ever change treatment. Likewise, isolated mandibular trauma with normal occlusion, no suspicion of open fracture, and a negative tongue blade test is very unlikely to be associated with a mandibular fracture that needs immediate attention. Although the tongue blade test may occasionally miss a coronoid process fracture, these rarely require any definitive treatment, and a delayed diagnosis usually is not associated with morbidity.

2. Become familiar with dental anesthetic techniques, as ED treatment often cannot be successfully performed without removing the patient's pain first. An individual with a fracture through the pulp will allow manipulation if the tooth is numb. They most certainly will not if each contact with the tooth is exquisitely painful. Dental anesthesia will

not only speed up the delivery of care, but also will increase patient satisfaction.

3. Learn the proper dental terminology so that discussions with consultants are concise and mutually understandable.

4. Storing a proper dental tray or kit in the ED will prove invaluable and time-saving. It is often the case that the emergency physician has to search for CaOH paste or other suitable materials from the pharmacy. This is often frustrating, time-consuming, and, unfortunately, fruitless. Being prepared prior to the emergency is what we are trained for, and we should not approach dental emergencies any differently than other emergencies we encounter.

5. Routine laboratory testing should not be performed on patients who present for dental bleeding except when anticoagulation, intractable vomiting, or liver disease are present. ▲

stood method of classification is based on a description of the injury.³

Crown Fractures

Crown fractures may be divided into complicated and uncomplicated categories. Uncomplicated crown fractures involve the enamel alone or the dentin in combination with the enamel.

Uncomplicated Crown Fractures Through The Enamel Only (Ellis Class I Fractures)

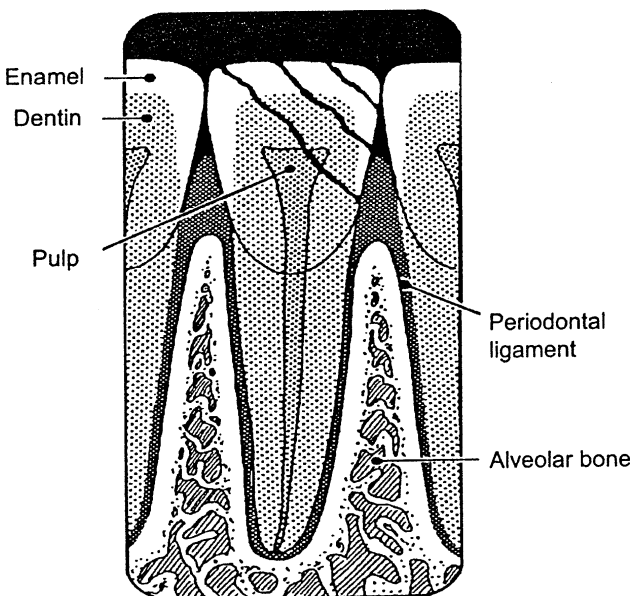
Uncomplicated crown fractures through the enamel only (Ellis class I fractures) are usually not sensitive to forced air, temperature, or percussion and usually pose no threat to the dental pulp. Immediate treatment is not necessary but may consist of smoothing the sharp edge of the tooth with an emery board or rotary disk sander. It is important to reassure the patient that a dentist can restore the tooth to its normal appearance using composite resins and bonding materials. Follow-up is important, as pulp necrosis and color change can rarely occur (0%-3%).^{3,22} (See Figure 6 and Figure 7.)

Uncomplicated Fractures Through The Enamel And Dentin (Ellis Class II Fractures)

Fractures that extend into the dentin are at a higher risk of pulp necrosis and need more aggressive treatment by the emergency physician. (See Figure 6 and Figure 8.) The risk of pulp necrosis in these patients is 1%-7%, but this increases as treatment time extends beyond 24 hours.³

Figure 6. Crown fractures.

Uncomplicated crown fractures involve (Ellis Class I) the enamel only, and (Ellis Class II) the enamel and dentin. *Complicated* crown fractures involve (Ellis Class III) the enamel, dentin, and pulp.



Used with permission from: Montgomery M, Redding S. *Oral-Facial Emergencies*. 1st ed. Portland, OR: JBK Publishing, Inc.; 1994. Figure 7-1.

These patients often complain of sensitivity to extremes of temperature or forced air. *The physical examination reveals the yellow tint of the dentin as contrasted to the white hue of the enamel.* (Fractures that are closer to the pulp cavity will reveal a pink tinge to the dentin.) These patients are usually sensitive to percussion with a tongue blade. The porous nature of the dentin allows passage of bacteria from the oral cavity to the pulp, which may result in inflammation and infection of the pulp chamber. This occurs most commonly after 24 hours, but may occur sooner if the fracture site is closer to the pulp. Likewise, patients less than 12 years of age have a pulp/dentin ratio larger than in the mature adult and are at increased risk for pulp contamination. Younger patients, therefore, should be treated aggressively and should be seen by their dentist within 24 hours.⁴

The goal of treating dentin fractures is twofold: to cover the exposed dentin to prevent secondary contamination or infection, and to provide pain relief. After a tooth is covered in the ED, the dentist can later rebuild it with modern composites. A tooth block performed prior to any tooth manipulation allows for easier application of the dressing, since the procedure becomes relatively painless. Dressings that may be applied to the surface of the tooth include calcium hydroxide, zinc oxide, and

Figure 7. Uncomplicated fracture through the enamel.

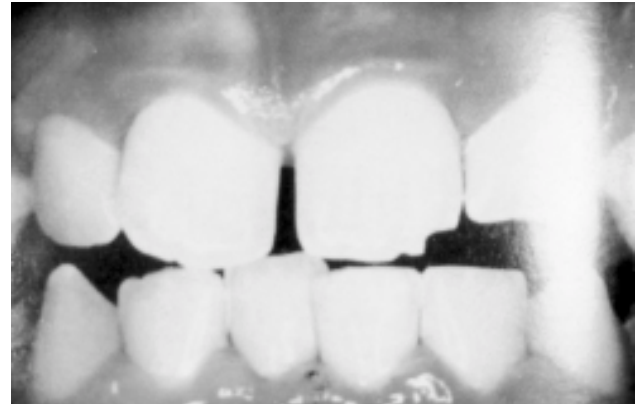
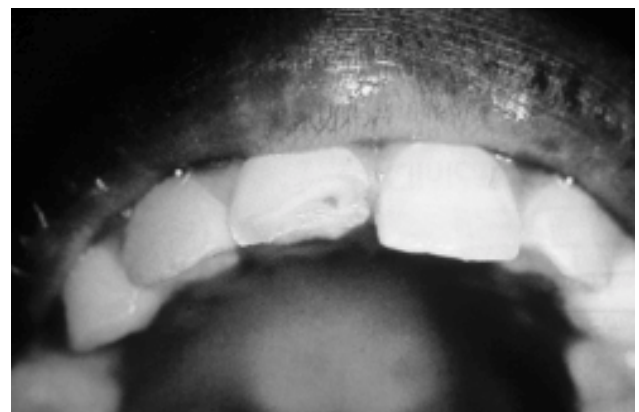

Figure 8. Fracture through the dentin.



glass ionomer composites.^{10,19,23,24} The literature suggests that glass ionomer dressings may be slightly superior to other dressings when applied by dentists; however, this is debated in the dental community. The ease of applicability of calcium hydroxide paste, however, and the fact that it can be used easily by itself make it attractive for use in ED patients.^{19,21} Composites that are cured with a bonding light are beyond the scope of most emergency practice. Skin adhesives and bone wax are sometimes used in the ED. They are not recommended, however, as bone wax is relatively porous, and skin adhesives are not approved for intraoral use. Most dressings are available as a catalyst and a base and are easily mixed with a dental spatula and mixing pad.

A commonly used ED dressing is calcium hydroxide (CaOH) paste, which is mixed and applied to the fractured surface of the tooth. CaOH preparations include both catalyst and base and pre-mixed formulations. (Two brands are Dycal and Pulpdent, which are available at www.dentalbox.net, www.smartpractice.com, www.pattersondental.com, and www.henryschein.com.) The tooth surface should be as dry as possible before application to ensure adherence. This can be accomplished by having the patient bite into gauze pads prior to application. The calcium hydroxide will dry within minutes after being exposed to the moist environment of the mouth. Although placing dental foil over the CaOH paste has been recommended, it is not necessary if the patient follows up within 24-48 hours. The patient should be instructed to eat soft foods until seen by the dentist to prevent dislodging of the dressing. Some practitioners begin antibiotic treatment if the period of exposure is significantly long.^{4,10} Penicillin or clindamycin offers good oral flora coverage.²⁵ Many patients sustaining a fracture through the dentin will eventually require a root canal or other definitive endodontic treatment. The timely application of an appropriate dressing in the ED, however, may prevent contamination of the pulp and make root canal unnecessary. As with any trauma to the anterior teeth, it is advisable to explain to the patient that disruption of the neurovascular supply is possible and that long-term complications such as pulp necrosis, color change, and root resorption may occur.

Complicated Fractures Of The Crown Involving The Pulp (Ellis Class III Fractures)

Complicated fractures of the crown that extend into the pulp of the tooth are true dental emergencies. (See Figure 9 and Figure 10.) These fractures result in pulp necrosis in 10%-30% of cases, even with appropriate treatment.³ *They are distinguished from fractures of the dentin by the pink color of the pulp.* The fracture surface of the tooth should be wiped off with gauze and observed for frank bleeding or a pink blush, which indicates exposure of the pulp. Fractures through the pulp are often excruciatingly painful, but occasionally there is a lack of sensitivity secondary to a disruption of the neurovascular supply of the tooth.²³

Immediate management includes referral to a

dentist, oral surgeon, or endodontist. The patient often requires a pulpectomy (complete removal of the pulp) or, in the case of primary teeth, a pulpotomy (partial removal of the pulp) as definitive treatment.^{22,24} The longer the pulp is exposed, the greater the chance of contamination and abscess formation. If a dentist cannot see the patient immediately, the emergency physician should attempt to relieve the pain and cover the exposed pulp. Supraperiosteal infiltration (dental block) should be performed if significant pain is present. Subsequently, the tooth should be covered with one of the dressings described in the preceding section. Sometimes bleeding is brisk and needs to be controlled before the application of a dressing. This can usually be accomplished by having the patient bite into a gauze pad that has been soaked with a topical anesthetic containing a vasoconstrictor such as epinephrine. Alternatively, a small amount of the anesthetic/vasoconstrictor may be injected into the pulp to control bleeding. After the covering is applied, instruct the patient to stay on a liquid diet and see the dentist as soon as possible. No more than 24 hours should lapse before definitive treatment is initiated. Antibiotic coverage should be considered as described the preceding section if exposure was prolonged.^{4,10}

There are currently no randomized, controlled trials

Figure 9. Fracture through the pulp.

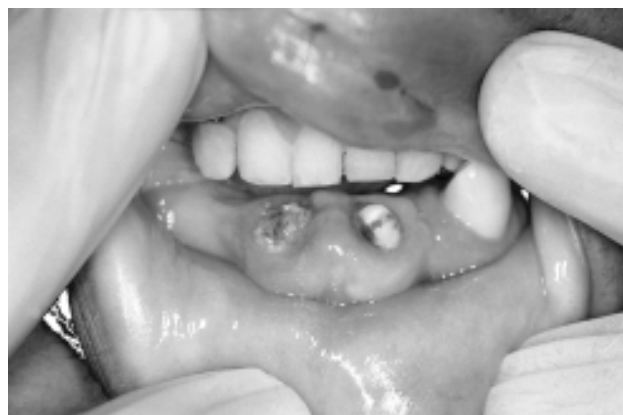
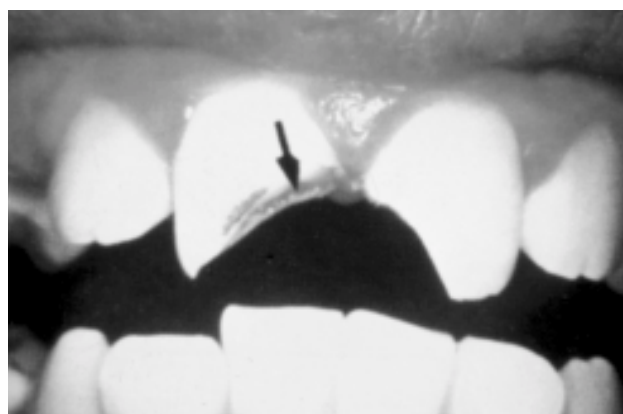
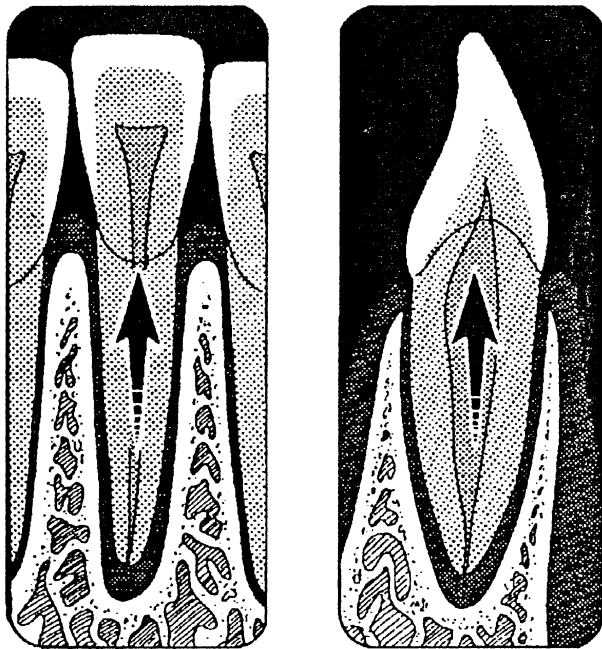
Figure 10. Complicated fracture through the pulp.



that address the question as to whether antibiotics should be prescribed for fractured teeth seen in the ED. Patients who present to the dentist and then undergo definitive treatment do not routinely receive antibiotic prophylaxis.^{19,24} However, in the ED, we must treat dental

Figure 11. Extrusive luxation.

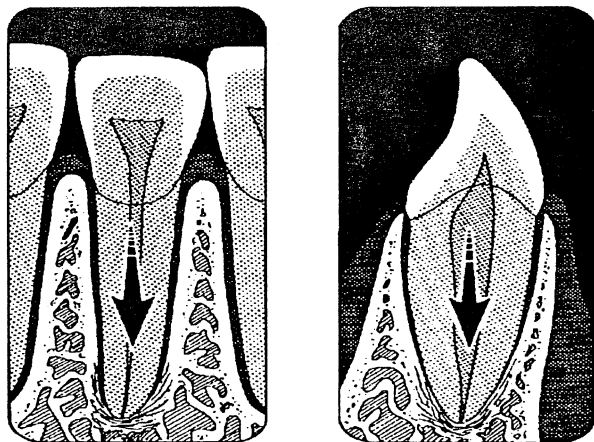
Extrusive luxation occurs when the tooth is forced partially out of the socket in an axial direction.



Used with permission from: Montgomery M, Redding S. *Oral-Facial Emergencies*. 1st ed. Portland, OR: JBK Publishing, Inc.; 1994. Figure 7-4.

Figure 12. Intrusive luxation.

Intrusive luxation of a tooth compresses the periodontal ligament and vascular supply of the pulp and may crush the apical bone.



Used with permission from: Montgomery M, Redding S. *Oral-Facial Emergencies*. 1st ed. Portland, OR: JBK Publishing, Inc.; 1994. Figure 7-5.

fractures with the following assumptions: first, it is uncertain as to whether the patient will be able to secure rapid dental follow-up, and second, it is usually unknown what the patient's underlying dentoalveolar health is. Delayed fracture care and poor gingival health increase the risk of pulp necrosis and, potentially, periapical abscess. These factors suggest to some that tooth fractures that involve the dentin or pulp should receive antibiotic prophylaxis.

Removal of the pulp with specialized instruments by the emergency physician is not recommended, although some authors have recommended this in the past. This procedure is in the realm of the dental professional and can result in complications if not done properly.

Luxation, Subluxation, Intrusion, And Avulsion

Subluxation refers to teeth that are mobile but not displaced, and luxation refers to teeth that are displaced, either partially or completely, from their sockets. Luxation injuries are divided into four types:

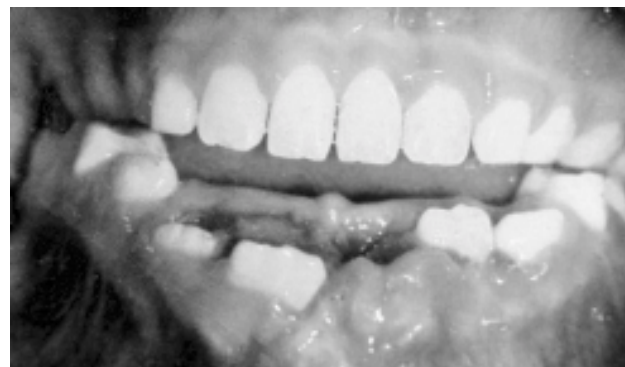- *Extrusive luxation*: The tooth is forced partially out of the socket in an axial direction. (See Figure 11.)
- *Intrusive luxation*: The tooth is forced apically and may be accompanied by crushing or fracture of the apex of the tooth. (See Figure 12 and Figure 13.)
- *Lateral luxation*: The tooth is displaced either facially, mesially, lingually, or distally. (See Figure 14 on page 14.) This injury is often associated with injuries to the alveolar wall.
- *Complete luxation*: Also known as complete avulsion, the tooth is entirely lost from the socket. (See Figure 15 on page 14.)

Teeth that are minimally mobile and are not displaced do very well with conservative treatment only. The tooth will tighten up in the socket if not re-traumatized. Patients should be instructed to eat only a soft diet for 1-2 weeks and follow up with their dentist as soon as possible.

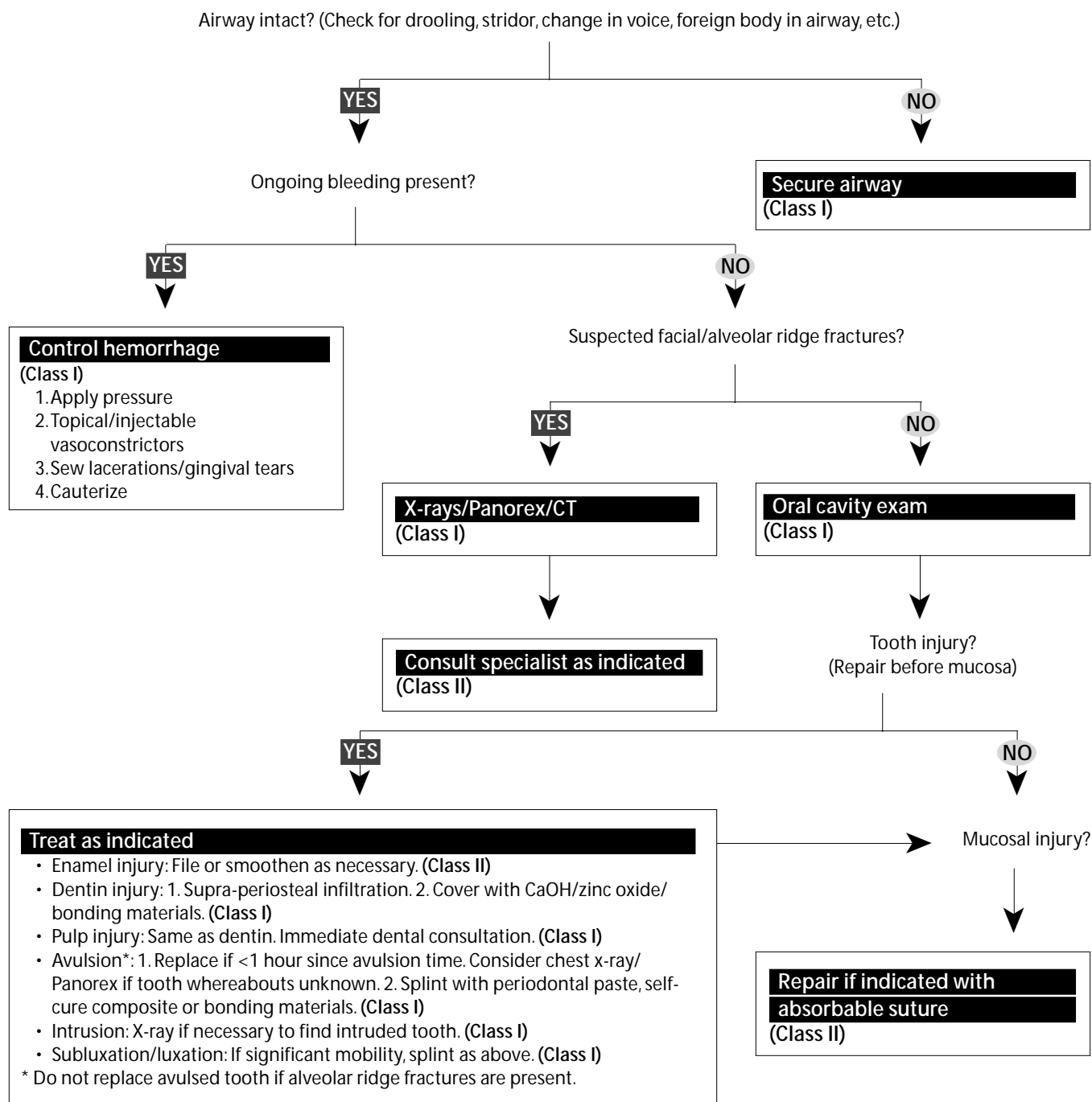
Grossly mobile teeth require some form of stabilization as soon as possible. In certain patients with poor gingival health, luxated teeth may not be salvageable due to disease of the attachment apparatus. Fixation is best

Continued on page 14

Figure 13. Intrusion of the anterior teeth.



Clinical Pathway: Approach To The Patient With Dental Trauma



The **evidence for recommendations** is graded using the following scale. For complete definitions, see back page. **Class I:** Definitely recommended. Definitive, excellent evidence provides support. **Class II:** Acceptable and useful. Good evidence provides support. **Class III:** May be acceptable, possibly useful. Fair-to-good evidence provides support. **Indeterminate:** Continuing area of research.

This clinical pathway is intended to supplement, rather than substitute for, professional judgment and may be changed depending upon a patient's individual needs. Failure to comply with this pathway does not represent a breach of the standard of care.

Copyright ©2003 EB Practice, LLC. 1-800-249-5770. No part of this publication may be reproduced in any format without written consent of EB Practice, LLC.

Ten Pitfalls To Avoid

1. "We didn't have anything to put the tooth in, so we just left it out. They can just get an implant anyway."

Milk suffices just fine for temporary avulsed tooth storage until you are ready to reimplant it. Every attempt should be made to reimplant and, therefore, preserve an avulsed tooth. Every person clearly is not a candidate for implants, and the practitioner should not make this supposition.

2. "I was always taught that you replace a tooth as soon as possible. What difference does it make if it's a kid or not?"

Primary teeth are best not reimplanted. They can certainly cause problems such as infections and disruptions of the secondary teeth. If there is a question as to whether a tooth is a primary tooth, first replace the tooth and then obtain an x-ray. If you see the secondary teeth have not yet erupted, you can always remove the primary tooth. Likewise, as long as the patient is referred expeditiously (within 48 hours) to a dentist, the dentist can remove the replaced tooth.

3. "My kid looks as if he was in a horror movie. That ER doctor never told me he could have discoloration in his tooth from a simple bump."

Any trauma to the teeth can result in pulp necrosis and permanent change in the coloration of the tooth. Although the dentist can usually repair this with bleaching or restoration, it is important that you warn patients who sustain tooth trauma that they may have discoloration.

4. "It's not really important that you aspirate before you inject when doing a dental block. That's just for beginners. How was I supposed to know he would develop that huge hematoma?"

Aspiration is extremely important when performing any dental blocks. It is a simple and important means to diminish side effects and complications. Intravascular injection can lead to cardiovascular effects, syncope, hematomas, and palpitations.

5. "He didn't have a cough or shortness of breath. There was no way to know he aspirated his tooth during that fight."

When a tooth has been avulsed and its location is unknown, obtain a chest x-ray if there is a question that it may have been aspirated. Removal of a tooth is easier prior to the development of pneumonia/empyema or effusion.

6. "I didn't see the tooth and, therefore, I assumed that it was avulsed. There was no way to tell it was pushed up into the gingiva and that it would cause an abscess."

The clinician must have a high index of suspicion in patients with intruded teeth. They often have the appearance of avulsed teeth. Intruded teeth can lead to abscesses and growth abnormalities if not diagnosed. X-ray if there is any question.

7. "I just assumed that the change in his voice was laryngitis. I figured the antibiotics would be good for his dental abscess and his pharyngitis."

Deep space infections of the neck can be very serious and occasionally life-threatening. Bilateral extension, change in voice, drooling, or difficulty swallowing or breathing are indications of a serious deep space infection. These patients require admission, IV antibiotics, CT scanning to delineate the extent of tissue spread, and oromaxillofacial/oral surgery consultation.

8. "There was no way I could have sewn that kid's tongue. He was thrashing all over the place. They usually heal fine anyway."

Tongue lacerations that are gaping or involve the tongue margin should be repaired. Epithelialization of a significant non-repaired tongue laceration can result in a bifid tongue or a grooved tongue. Both of these conditions can be difficult for plastic surgeons to repair. Repair of difficult tongue lacerations may require sedation or referral to a specialist.

9. "We don't have anything to cover fractured teeth in our ED and the patient didn't have any insurance. I told him to follow up in the university dental clinic."

Teeth that have been fractured through the pulp have a high incidence of pulp necrosis and tooth loss if not treated. Immediate covering in the ED can, occasionally, prevent root canal. It will also help with pain by keeping the nerve covered and decrease the chance of abscess or pulpitis. Immediate referral usually will result in root canal for fractures through the pulp, but the patient will keep a functional tooth.

10. "I always thought that penicillin was fine for deep space infections of the neck."

Penicillin or clindamycin alone are adequate for suspected periapical abscesses, but broader coverage should be instituted for deep space infections of the neck. Penicillin should be used in conjunction with metronidazole. Alternatives include the expanded-spectrum penicillins such as ticarcillin/clavulanic acid, piperacillin/tazobactam, or clindamycin plus cefoxitin. Far more important than antibiotics is surgical consultation. ▲

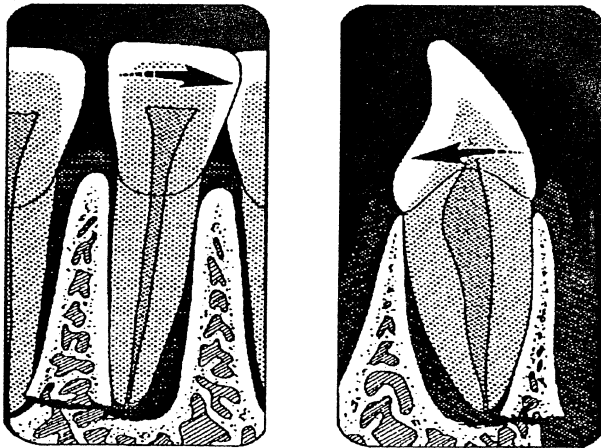
Continued from page 11

performed by the dental specialist with enamel bonding materials or wire ligation. Although many different home remedies exist for splinting loose teeth in the ED, one must be aware of the concern for aspiration of teeth or the splint if the splint should fail. The physician should also avoid the use of non-approved medications in the mouth. An example would be the use of skin adhesives, which, to date, have not been approved for intraoral use.

Temporizing splinting techniques suitable for use by emergency physicians include periodontal paste and self-cure composite. A commercially available form of periodontal paste known as Coe-Pak consists of a base and a catalyst that, when mixed together, form a moderately sticky clay-like dressing that becomes firm after application. The splint performs best if applied to the facial and oral surfaces of the teeth; however, it is usually sufficient to apply it only to the facial surface of the

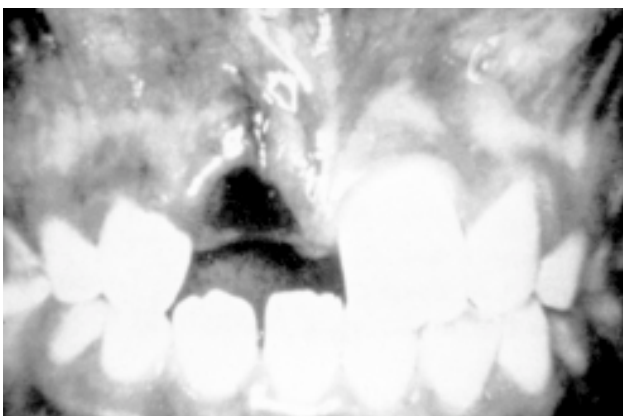
Figure 14. Lateral luxation.

Lateral luxation occurs when the tooth is displaced in either a lingual, mesial, distal, or facial direction. Fractures of the alveolus frequently accompany lateral luxation injuries.



Used with permission from: Montgomery M, Redding S. *Oral-Facial Emergencies*. 1st ed. Portland, OR: JBK Publishing, Inc.; 1994. Figure 7-6.

Figure 15. An avulsed tooth.



affected teeth. Coe-Pak is most easily applied when the physician's gloves are moistened with water or lubricating jelly and the gingiva and enamel are completely dry. It is important to apply the dressing into the grooves between the teeth as well as to the adjacent teeth, and the patient should be reminded to eat a soft diet until seen for follow-up in 24 hours.

Self-cure composite is another splinting option in the ED. Although many composites used in the dental office require a curing "light" and etching acids to affix the bonding material, self-cure composite requires neither and is easy to use. It is applied only to the enamel of the involved tooth, not the gingiva, and to the adjacent non-mobile teeth. Both periodontal paste and self-cure composites are easy to remove during formal restoration by the dentist.

Teeth that are luxated in either the horizontal or axial planes or are slightly extruded can also be splinted using the preceding techniques. The teeth do not need to be in perfect alignment prior to discharge from the ED. Final adjustments can be made in the specialist's office.

Intrusion And Avulsion

Intruded teeth have been forced apically into the alveolar bone and often result in disruption of the attachment apparatus or fracture of the supporting alveolar bone. This is especially common in permanent teeth with mature roots.⁷ Intruded teeth are often immobile and, therefore, do not require stabilization in the ED, but often do require later endodontic treatment because of pulp necrosis. It is very important to consider the possibility of an intruded tooth if there is an abnormal space in the dentition, as these can cause infection and craniofacial abnormalities if undiagnosed. X-rays should be obtained anytime there is uncertainty as to whether a tooth is intruded or avulsed. The dental specialist should manage intruded teeth, and referral should take place within 24 hours. Permanent teeth often require repositioning and immobilization, but primary teeth are usually given a trial period to erupt on their own before any intervention is taken.

Avulsed teeth are true dental emergencies. The first question to ask is, "Where is the tooth?" Missing teeth may be intruded, aspirated, fractured, swallowed, or embedded in the oral mucosa somewhere. Radiography including Panorex, facial films, or a chest x-ray may need to be considered to find fragments of fractured teeth or an avulsed tooth. ED management is based on a number of factors, including patient age, time elapsed since avulsion, presence of other maxillofacial trauma such as alveolar ridge fractures, and the overall health of the periodontium.⁷ *Primary teeth are not replaced because they can fuse to the alveolar bone and potentially cause craniofacial abnormalities or infection, and they may prevent normal eruption of the permanent teeth.*²⁶ There are small reports of successful reimplantation of primary teeth by dentists; however, most resources do not recommend it be performed by dentists, family members, or emergency physicians.²⁵ Reimplanted primary teeth may also

interfere with the eruption of the secondary teeth. Parents can be reassured that prosthetic replacements can be worn until the permanent teeth erupt, if desired.

Time is the essential consideration when deciding whether to replace an avulsed tooth. In general, the longer the tooth is out of the socket, the higher the incidence of periodontal ligament necrosis and subsequent failure of reimplantation.⁷ Periodontal ligament cells generally die within 60 minutes outside of the oral cavity if they are not placed in an appropriate transport medium.⁴ Significant research has been conducted on different media used to keep the cells of the periodontal ligament alive. Various transport media, including milk, Hank's balanced salt solution, Save-A-Tooth, saliva, water, and Gatorade, have all been studied. Certain cell culture media have been developed that cause periodontal ligament cells to proliferate and remain viable, but milk and the commercially available Save-A-Tooth are best for both prehospital care and ED storage.²⁷ Both milk and Save-A-Tooth (a commercial version of Hank's balanced salt solution) preserve the periodontal ligament for at least 8-12 hours; however, reimplantation should take place at the earliest opportunity. The critical factor is to get the tooth into some sort of transport medium, because even 5-10 minutes outside some kind of storage medium can cause desiccation and death of the periodontal ligament cells. Saline should be used at the scene if nothing else is available, and the patient or prehospital providers should reimplant the tooth if possible. Saliva and water are less desirable alternatives, although saliva is preferable to water.²⁸ If the medics or the patient is reluctant to do this or there are conditions preventing reimplantation in the field, it will need to be done on arrival using the following guidelines:

1. Store the tooth in an appropriate medium if reimplantation is delayed for any reason.
2. It is very helpful to perform a supraperiosteal infiltration prior to the manipulation or replacement of teeth. This makes the procedure more comfortable for the patient and easier for the physician to perform. Regional blocks also are acceptable and are especially useful if more than one tooth is involved.
3. Check the oral cavity for trauma. If an alveolar ridge fracture is present or the socket is severely damaged, the tooth should not be reimplanted.
4. If available, suction the socket first with a Frasier tip suction catheter to remove any accumulated clot. Overly aggressive suctioning can damage the periodontal ligament fibers lining the socket. Next, gently irrigate to remove any remaining clot. Reimplantation and realignment is difficult if the clot is not entirely removed. Debris on the tooth should be gently rinsed, *not scrubbed*, with saline. It is better to reimplant the tooth with a small amount of debris present than to wipe off the periodontal ligament. Implant the tooth using firm, but gentle pressure.
5. The tooth will require splinting (see above) after reimplantation if it is still loose, although teeth that are still very mobile after reimplantation

are less likely to develop firm attachment of the periodontal ligament.

6. Update the patient's tetanus prophylaxis as necessary and send him or her home on a soft diet.

Antibiotics are controversial in the management of fractured and avulsed teeth. Although the American Association of Endodontics does not recommend the routine use of antibiotics for fractures or avulsions, other authors recommend the use of antibiotics that cover mouth flora (such as penicillin or clindamycin) to decrease the inflammatory resorption of the root.^{3,8} It is probably prudent to use antibiotics if the root is heavily soiled; otherwise, treatment should be tailored to the individual patient and discussed with the consultant.

The prognosis is dependent on many things, the most critical being time to reimplantation. Likewise, the age of the patient, the stage of development of the root (younger is better), and the overall health of the gingiva are also very important.

The goal of the emergency physician in any tooth avulsion or fracture is to keep the native tooth if possible. A tooth that has been reimplanted usually loses the majority of its neurovascular supply and undergoes pulp necrosis. If the periodontal ligament stays intact, however, the likelihood is greater that the tooth will remain functional. It is important to remind the patient that after reimplantation, some root resorption is inevitable and there is always the chance that tooth loss may occur.

Alveolar Bone Fractures

Trauma to the anterior teeth may result in fractures of the alveolus, which is the tooth-bearing portion of the maxilla or mandible. Alveolar ridge fractures often occur in multi-tooth segments and will vary in the number of teeth involved, the amount of displacement, and the amount of the mobility of the affected segment. The diagnosis is often obvious as the examination is notable for a section of teeth that are misaligned and mobile. Dental bitewing x-rays confirm the diagnosis and Panorex or facial films may show the fracture line apical to the roots of the involved teeth. (However, these films are often inconclusive or normal.) In addition, most EDs don't have the capability of doing dental bitewing films.

Treatment of these fractures involves rigid splinting of the affected segment, which should be done urgently by an oral surgeon or dentist. *This should ideally be done as soon as possible within 24 hours.* The urgency is dependent upon the mobility, the extent, and the displacement of the involved segment. For example, a fragment that is large and very mobile would present an aspiration risk and should be fixed immediately. Likewise, an open fracture would need immediate attention. A stable, small segment could be repaired in 48-72 hours. The role of the emergency physician is to identify the injury as well as any avulsed or fractured teeth and preserve as much of the alveolar bone and surrounding mucosa as possible. Alveolar bone that is lost, debrided, or missing is difficult for the specialist to restore properly.²¹

Lacerations And Dentoalveolar Soft-Tissue Trauma

It is imperative for the emergency physician to carefully inspect all wounds and lacerations of the perioral region and determine whether any foreign bodies are present. Through-and-through lacerations are easily overlooked, as are small foreign bodies and tooth fragments.

Generally, the repair of injured teeth should take place prior to soft-tissue repair, as soft-tissue manipulation (as would occur during repair of tooth injuries) can result in damage to sutures already placed in the soft tissue. The repair of oral lacerations follows standard wound repair principles.

The rates of infection of intraoral lacerations are extremely small, and most heal uneventfully without antibiotic coverage. One prospective study showed a trend toward decreased infections in intraoral lacerations treated with prophylactic penicillin; however, the results were not statistically significant.²⁹ Some practitioners use antibiotics if a significant amount of devitalized or crushed tissue is present or if the wound is through-and-through. Coverage of oral flora (penicillin or clindamycin) is adequate for mouth lacerations, whereas additional skin coverage (clindamycin or dicloxacillin) is sometimes employed for through-and-through lacerations.

The emergency physician will inevitably be faced with the following challenging injuries.

Buccal Mucosa Injuries

Most lacerations and abrasions of the buccal mucosa heal quickly and rapidly and don't require repair. Large lacerations (> 1-2 cm) should generally be repaired using 4-0 or 5-0 chromic sutures. Absorbable sutures should be placed so that the knots are buried. Silk has been recommended as an alternative and is acceptable, but it has a higher reactivity and will need to be removed after healing. Avoid nylon sutures, as they are sharp and irritating to tissue.

Through-and-through lacerations can present a sticky situation. The integrity of the Wharton's and Stenson's ducts as well as the facial nerve needs to be established prior to repair. Clues to ductal injury include saliva leaking from the wound or blood at the orifice of Stenson's duct (which exits in the buccal mucosa at the level of the upper second molar). The Wharton's duct exits the buccal mucosa under the tongue in the midline and also should be examined for bloody drainage.

Test all five branches of the facial nerve for integrity:

- To test the temporal branch, ask the patient to contract his or her forehead and elevate his or her brow.
- Test the zygomatic branch by having the patient open and shut his or her eyes.
- Evaluate the buccal and mandibular branches by having the patient smile and frown.
- Check the cervical branch by having the patient contract the platysma muscle.

Guidelines for closure are controversial, but generally, larger lacerations (> 1 cm) should be closed.³⁰ The

mucosa is repaired as described, and the skin is closed with 6-0 nylon, prolene, or rapidly absorbable suture. Close the mucosa first so as not to disturb the skin layer. If the intraoral wound is very small or is a puncture wound, it is reasonable to close only the skin layer.

Large lacerations, through-and-through lacerations, or lacerations with large amounts of devitalized tissue should be rechecked in a couple of days. Facial sutures are removed in five days. Saline rinses and a soft diet should be prescribed.

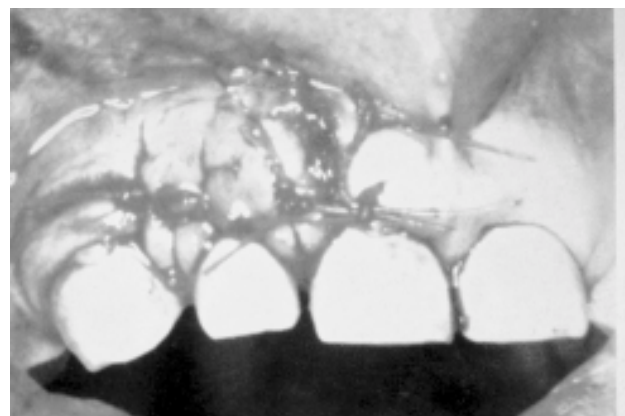
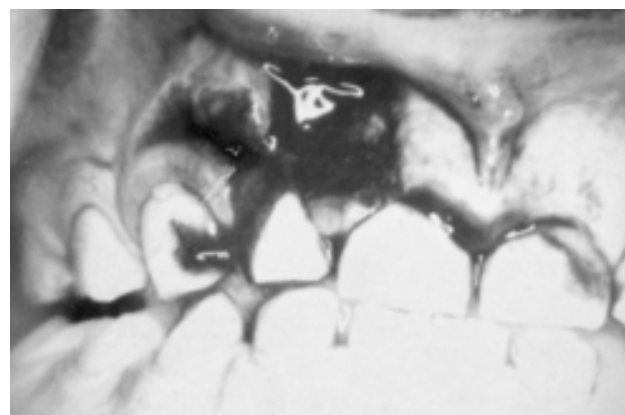
Gingiva Injuries

Small lacerations over the maxillary or mandibular gingiva usually heal uneventfully without intervention. If the laceration is large, gaping, there is bone exposed, or if a flap is present, you should approximate the edges with 4-0 or 5-0 absorbable suture. As mentioned, silk is a rarely used option. If difficulty arises because there is little soft tissue underneath the gingiva to anchor your suture, then superficially wrap the suture around the teeth and use them as anchors for your suture. (See Figure 16 and Figure 17.)

Frenulum Injuries

The maxillary frenulum rarely requires sutures for simple lacerations, but more complex lacerations extending into

Figure 16 and Figure 17. Wrapping the suture around the teeth to assist in repairing the gingiva.



the surrounding mucosa or gingiva should be approximated with absorbable suture. These wounds are painful! Even if suturing is not required, analgesia should be prescribed in many cases. The lingual frenulum is very vascular in nature and may need a suture or two to control hemostasis. A local anesthetic with a vasoconstrictor aids in hemostasis while the wound is repaired.

Tongue Injuries

Most tongue lacerations that are less than a centimeter and whose wound edges are not gaping do not require repair.³⁰ Lacerations that gape widely need sutures, as the cleft left by the non-repaired wound will epithelialize, leaving a grooved or bifid appearance. Likewise, wounds that are bleeding profusely, are flap-shaped, or are on the edge of the tongue should be sutured. Small avulsions heal without intervention.

The securing of the tongue is the challenging part of this repair. Explaining the procedure to the patient in detail before proceeding goes a long way in determining success. Have an assistant hold the tongue with gauze or, if necessary, use a towel clip on the end of the anesthetized tongue to hold the tongue in place. An assistant can also pull the tongue out of the mouth using a suture placed through the tip of the tongue. Children with tongue lacerations that need to be repaired may require procedural sedation or repair by a specialist in the surgical suite, but fortunately most pediatric tongue lacerations are small and heal uneventfully without suture repair.³⁰

Repair should be initiated with anesthesia, either locally or via a lingual block. For the repair, 4-0 absorbables are ideal to use, but silk can be used as well. Silk has the advantages of being smooth and nonirritating to tissues as well as secure, but it must be removed in 5-7 days. Deep lacerations extending into the muscle can be closed with one deep stitch penetrating both the mucosa and the muscle. Bury the knots of absorbable sutures as they often work their way loose with the constant movement of the tongue. Full-thickness lacerations can be closed in a number of ways. Suturing all three layers together is acceptable, as is the technique of closing the top mucosa and muscle with one layer and, subsequently, doing the same thing on the underside of the tongue. Bleeding is almost always controlled with primary repair, as described in the following section.

Hemorrhage

Bleeding from the oral cavity is commonly associated with dental procedures. Often, when that bleeding is delayed, it is the emergency physician who must control the problem. First, ascertain whether it was dental work that caused the problem. Spontaneous bleeding of the oral cavity or gingiva not associated with dental manipulation or trauma suggests advanced periodontal disease or a systemic process.

Gingival bleeding after scaling or other minor routine dental procedures is usually controllable with direct pressure and saline/hydrogen peroxide rinses.

Bleeding that persists from the gingival areas despite pressure and rinses should raise suspicion for bleeding abnormalities, the majority of which are medication-induced. Much more common is hemorrhage arising after a molar has been extracted. These patients usually present when the dentist cannot be contacted and after many futile attempts to stop the bleeding at home. There are a number of options available in the ED to control this type of bleeding:

- Apply direct pressure. Patients have probably been doing this at home, but a couple of simple techniques make it more effective. Any excessive clot that has built up around the oozing site should be removed with a suction catheter after giving a local anesthetic. Gently irrigate the socket. Adherent clot can be left intact. Next, insert a dental roll gauze (dental tampon) over the bleeding site, covered by 2 x 2s. Dental roll gauze has the advantage of fitting more precisely between the teeth and, therefore, affords more pressure. It helps to moisten the gauze with a topical vasoconstrictor such as epinephrine. Instruct the patient to bite down and hold for 15 minutes or so.
- If bleeding persists after 15 minutes, infiltration with an anesthetic containing a vasoconstrictor should be performed. Infiltrate the bleeding area and the gingiva surrounding the socket with lidocaine and epinephrine (1:100,000) until blanching occurs. Reapply the gauze over the site and instruct the patient to bite down for another 15 minutes. The injection serves two purposes: it causes vasoconstriction, and it anesthetizes the area so that adequate pressure can be generated during biting.
- If bleeding persists, insert coagulating agents (such as Gelfoam, Surgicel, Avitene, or Instat) into the socket and then loosely close the gingiva surrounding the socket with silk suture. Instruct the patient to bite down on gauze placed over the sutures.
- Electrocautery works extremely well. Thermal cautery units that use battery power and do not require the patient to be grounded are available. Anesthetize the site prior to cauterization.
- If the preceding measures are not effective in controlling bleeding, consult a specialist. It is also reasonable to consider the use of fresh frozen plasma or platelets if a coagulopathy is determined to be present.

Patients whose bleeding can be controlled can be discharged and instructed not to take anything by mouth for four hours and then only cold liquids and soft foods. Silk sutures require removal in seven days.

Alveolar Osteitis

Alveolar osteitis (dry socket) pain can be severe and often requires definitive treatment. Alveolar osteitis is a localized osteomyelitis that occurs when the alveolar bone becomes inflamed. This occurs when the clot normally present in the tooth after a tooth extraction

becomes dislodged or dissolves. It is most common 2-4 days following a tooth extraction. The examination is usually unremarkable, with the exception of the missing clot (which isn't always obvious to the non-experienced practitioner). Smoking, drinking from a straw, hormone replacement, and periodontal disease predispose the patient to a dry socket. Only 2%-5% of patients ever develop a dry socket; however, this number increases with traumatic extractions or impacted third molars.^{10,31}

If a patient presents with pain several days after an extraction and a relatively normal examination, dry socket is likely. The pain is rarely relieved with traditional pain medications, but a dental block provides immediate relief. The alveolar osteitis can be adequately treated after the pain is relieved. Irrigate the socket and gently suction any accumulated debris with a Frasier tip suction catheter. Next, the socket must be filled, which will prevent recurrence of pain and allow healing to begin.

The socket may be packed with gauze that is impregnated with eugenol (oil of cloves) or a local anesthetic. These can be obtained from the hospital pharmacy. The gauze tends to dry out and loosen; therefore, it needs to be replaced in 24-36 hours. Patients should see their dentist the next day or return to the ED so that the packing can be replaced. The socket may also be packed with a slurry of Gelfoam and eugenol. The Gelfoam acts as a matrix to hold the eugenol in place. A commercial product, Dry Socket Paste (available at www.dentalbox.net, www.pattersondental.com, or www.henryschein.com) can also be applied by itself into the socket, or it can be mixed with Gelfoam as a thicker slurry. Dry Socket Paste is a very thick paste containing eugenol. It often stays in place longer than gauze and doesn't dry out. There are also other commercial products available for dry sockets from dental supply companies.

Antibiotics may be given to prevent alveolar osteitis, although they are rarely necessary once the socket has been packed. They should be prescribed at the discretion of the patient's oral surgeon or dentist.^{10,21,23}

Dentoalveolar Infections

Infections of the mouth run the gamut from minor, easily managed abscesses to severe, life-threatening deep space infections that require airway management and operative drainage. The most common dental infections that present to the ED are those related to pulp disease. Others are associated with the attachment structures of the teeth, such as the gingiva, periodontal ligament, and the alveolar bone. These infections are often chronic conditions, but over time they can progress to the point where periodontal abscesses form and emergency treatment is required. Emergency physicians will be called upon to drain abscesses of dental origin that do not extend into the deep spaces and that have well-defined boundaries that are easily accessible by intraoral or external drainage.

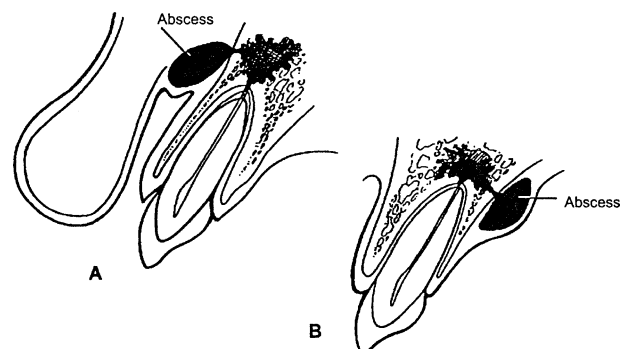
Diseases of the pulp can be secondary to trauma,

operations, or other causes, but clearly the most common cause is secondary to bacterial invasion after carious destruction of the enamel. As the enamel is destroyed, caries development progresses more rapidly through the dentin and into the pulp chamber, causing an inflammatory reaction termed pulpitis. If the erosion caused by the bacteria is large enough to drain the developing inflammation, the patient may be asymptomatic for a fairly long period of time. When the drainage becomes blocked, the process progresses to the pulp and the periapical space, causing exquisite tenderness.

A periapical abscess will follow the path of least tissue resistance, which may be through the alveolar bone and gingiva and into the mouth (see Figure 18), or the deep structures of the neck. If the infection has progressed apically through the alveolar bone and there is localized swelling and tenderness at the base of the tooth, incision and drainage is indicated. Abscesses of this type are usually visualized at the gingival margin. Incision and drainage is easily accomplished by making a stab incision with a #11 blade over the area of maximal fluctuance. Small abscesses probably do not need a drain placed; however, larger abscesses may benefit from a drain. A fenestrated drain or a piece of 1/4" gauze is acceptable and should be tacked to the mucosa with silk suture to prevent aspiration. Antibiotics are often prescribed.

In the ED setting, differentiation between periapical abscesses or simple pulpitis is difficult, and dental x-rays are seldom available. Therefore, in the absence of trauma or recent instrumentation, some physicians begin antibiotics if the patient complains of tooth pain and localized percussion tenderness exists. Routine antibiotics for tooth pain that is caused by non-infectious causes (pulpitis, instrumentation, etc.) or abscesses that are localized to the periapical region are not recommended by the dental societies.^{32,33} Antibiotics have been recommended for odontogenic infections that have spread outside the immediate periapical area or have associated systemic signs, such as fever, swelling, or trismus.

Figure 18. Perforation of labial and palatal cortex.



Used with permission from: Montgomery M, Redding S. *Oral-Facial Emergencies*. 1st ed. Portland, OR: JBK Publishing, Inc.; 1994. Figure 2-1.

There is clearly no set standard of care with regard to the prescribing of antibiotics in odontalgia. The dental literature does not recommend routine administration but, as noted, it is common practice. Analgesia should be provided as well. A supraperiosteal infiltration (tooth block) using a long-acting anesthetic should be performed in most cases as this not only provides immediate and long-acting relief, but it also decreases the requirement for narcotic analgesics once the anesthetic has dissipated.

Periodontal disease, unlike pulpal disease, is usually not symptomatic and, therefore, rarely is a reason to come to the ED. Periodontal disease refers to infection of the gingiva, the periodontal ligament, and the alveolar bone (essentially, the attachment apparatus of the tooth). Gingivitis is an inflammation of the gingiva caused by bacterial plaque. In advanced disease, the gingiva becomes red and inflamed and tends to bleed easily. If the disease is chronic, an abscess can form as organisms become trapped in the periodontal pocket. The purulent material usually escapes through the gingival sulcus; however, it can invade the supporting tissues, the alveolar bone, and periodontal ligament (periodontitis). Periodontal abscesses that are not draining spontaneously through the sulcus can be drained in the ED. Saline rinses are encouraged to promote drainage. Systemic antibiotics should be reserved for severe cases or for abscesses that cannot be drained. Chlorhexidine rinses can be substituted for saline for more severe disease. If you are uncertain whether the abscess is from the pulp or

the periodontium, antibiotics should be prescribed even if the abscess is drained.^{10,31}

Pericoronitis is an inflammatory condition that occurs when the gingiva overlying the erupting teeth becomes traumatized and inflamed (a common occurrence with the eruption of wisdom teeth). The gingiva overlying the crown may entrap the bacteria, and subsequent infection may develop. The localized infection can occasionally spread to deeper spaces such as the pterygomandibular or submasseteric spaces. Clinically, patients with spread of their pericoronal infections will present with trismus secondary to irritation of the masseter and pterygoid muscles. ED evaluation is directed at detecting regional spread to the deeper spaces. CT scanning may be helpful. Significant trismus or other systemic signs of advanced infection require IV antibiotics and urgent consultation for drainage procedures (and usually extraction of the offending tooth). If pericoronal infection is localized, saline rinses and oral antibiotics are prescribed with dental follow-up in 24-48 hours.

Deep Space Infections Of The Head And Neck

It is not unusual for odontogenic infections to spread into the various potential spaces of the face and neck. Presenting signs and symptoms consist of fever, chills, pain, difficulty with speech or swallowing, and trismus. (See Table 4.) Although certain teeth usually spread to particular contiguous spaces, the rapid spread of these infections often makes localizing the exact space involved

Table 4. Signs and symptoms of deep-space neck infections.

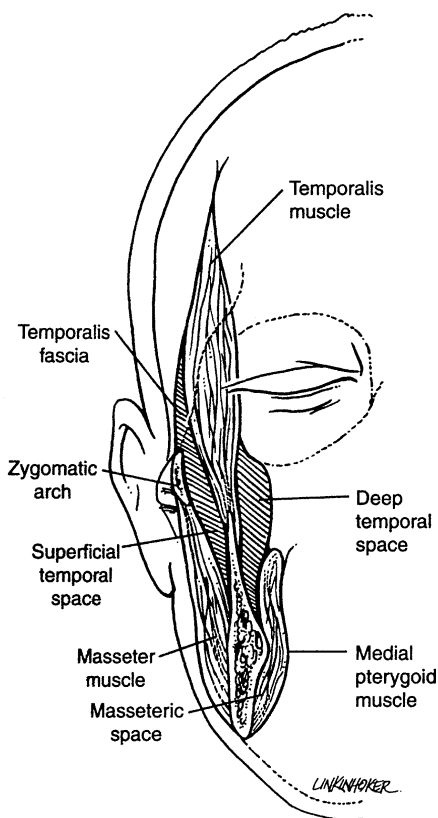
Space	Trismus	Dysphagia	Source	Edema	Unique Sign/Symptom
Peritonsillar	Minimal	Yes	Tonsil	Soft palate	Uvular deviation, hot-potato voice, otalgia
Submandibular (Ludwig's angina)	Marked	Yes	2nd and 3rd mandibular molars	Diffuse, collar	Brawny edema, firm floor of mouth
Parapharyngeal (lateral pharyngeal)	Severe	Yes	Teeth (odontogenic)	Tonsil, lateral pharyngeal wall ± soft tissue of neck	
Carotid sheath	Variable	Variable	Direct extension IV drug abuse, trauma	Sternocleidomastoid muscle	Pitting edema over sternocleidomastoid muscle, torticollis
Retropharyngeal	Yes	Yes	Upper respiratory infection, nasopharynx, sinuses	Unilateral bulge, posterior pharyngeal wall	± Drooling, cervical rigidity, hot-potato voice
Prevertebral	Variable	Variable	Direct extension trauma, tuberculosis	Midline bulge, posterior pharyngeal wall	± Drooling, cervical rigidity, hot-potato voice (tuberculosis may be chronic)
Pterygopalatine	Severe	No	Maxillary molars	Gingiva, face, or eye	
Masticator	Extreme	No	3rd mandibular molar	Posterior mandibular ramus	External swelling minimal compared to trismus
Visceral	Variable	Yes	Direct extension trauma	Variable	± Hoarseness, dyspnea, cutaneous emphysema

Used with permission from: Eisele DW, McQuone SJ, eds. *Emergencies of the Head and Neck*. St. Louis: Mosby; 2000. Table 19-1.

difficult. Infections may involve the buccal, temporal, submasseteric, sublingual, submandibular, parapharyngeal, and other regions. (See Figure 19 and Figure 20.) Maxillary extension of periapical abscesses can spread into the infraorbital space and, subsequently, to the cavernous sinus through the ophthalmic veins, resulting in cavernous sinus thrombosis. Cavernous sinus involvement is usually associated with periorbital cellulitis as well as meningeal signs or a decreased level of consciousness.

Periapical infections of the anterior mandibular teeth often spread to the buccinator space or the sublingual space, while those of the mandibular molars spread into the submandibular space. The submandibular space connects with the sublingual space. Bilateral involvement of both of these spaces is known as Ludwig's angina and can be life-threatening. Most cases of Ludwig's angina are caused by dental infections. Specific attention should be paid to the neck and the floor of the mouth during the physical examination. Woody induration of the tissues in the mouth floor or elevation of the tongue is indicative of spread of the infection across the midline. Airway precautions are of paramount importance.³⁴ As infection progresses, the submandibular, submental, and sublingual spaces all become edematous, and there may be elevation of the tongue and the soft tissues of the mouth.

Figure 19. Temporal spaces of the neck.



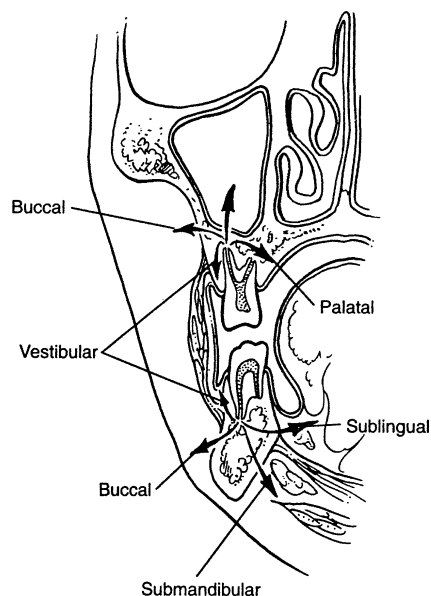
Used with permission from: Eisele DW, McQuone JS, eds. *Emergencies of the Head and Neck*. St. Louis: Mosby; 2000. Figure 16-2 (a).

The soft tissues of the posterior pharynx can also become involved. The suprahyoid region of the neck appears tense and indurated, and landmarks may be obscured.

The management of complicated odontogenic head and neck infections centers on airway management, surgical drainage, and antibiotics. If there is uncertainty as to whether the deep spaces are involved, CT scanning can delineate the extension of the infectious process.³¹ *CT scanning has become the imaging modality of choice for deep space infections of the head and neck as it can localize collections of cellulitis or abscesses that cannot otherwise be examined.*^{35,36} Airway intervention should be performed early if there is any question of compromise, and tracheostomy may be indicated.^{37,38} Surgical consultation with the appropriate specialist is mandatory. Intravenous antibiotics should be administered in the ED.

The bacteria involved are typically a mixed *Streptococcus/Staphylococcus* combination, but a mixed aerobic/anaerobic infection is also possible. More than 40% of isolates from odontogenic neck abscesses are resistant to beta-lactam antibiotics.³¹ Antimicrobials of choice include penicillin G plus metronidazole or expanded-spectrum penicillins such as ampicillin/sulbactam, ticarcillin/clavulanate, and piperacillin/tazobactam. These combination antibiotics are effective against beta-lactamase-producing bacteria and also cover anaerobes such as *Bacteroides fragilis*. Clindamycin is an effective choice when patients are allergic to penicillin and should be used in combination with a cephalosporin such as cefotetan or cefoxitin in order to cover resistant organisms. *In deep space infections, antibiotics are adjunctive therapy and not a substitute for surgical intervention.*

Figure 20. Location of temporal space abscesses.



Used with permission from: Eisele DW, McQuone JS, eds. *Emergencies of the Head and Neck*. St. Louis: Mosby; 2000. Figure 16-2 (b).

Special Considerations

Children

It is important to remember that primary dentition is very different than the permanent dentition, especially with respect to intrusion and avulsion. Intruded baby teeth are usually allowed to erupt, whereas permanent teeth that are intruded usually require repositioning and fixation. Avulsed primary teeth should not be replaced in the ED. If there is a question of whether a tooth is a permanent tooth or not, replace the tooth and consult the patient's dentist. The tooth can be removed in the office in a day or two if necessary. The other way to determine whether a tooth is permanent or not is to obtain a Panorex or facial films and look for the permanent tooth in the alveolar bone.

The Elderly

The elderly are much more likely to have prosthetic teeth, implants, or other appliances. This must be taken into consideration when determining what steps are necessary to best preserve the function of a traumatized or infected tooth. It is best to consult your dental colleagues when intervening in the patient with significant dental hardware.

The Immunosuppressed

The population least likely to have preventative dental care is perhaps also the population that is at risk for poorly treated chronic disease or infectious diseases that may alter immune function. Those patients with immunocompromised conditions are not only more susceptible to chronic dental disease such as periodontal disease, but they are also at higher risk for the development of deep space infections. Any patient who presents to the ED with severe dentoalveolar disease should be questioned about risk factors for HIV, diabetes, tuberculosis, malignancy, etc., and the appropriate testing and follow-up should be arranged.

Cutting Edge

Today's EDs are awash in technological advancement. Ultrasound, electronic charting, clot-busting medications, bedside testing, and other technologies have truly advanced medical care. Unfortunately, many EDs don't have the proper materials to take care of patients with simple dental problems. This is most likely secondary to lack of dental-specific training among emergency physicians, but also to an over-dependence on our dental colleagues and a perceived lack of importance of dental emergencies. Many medications, glues, pastes, and anesthetics are available to EDs, and our patients would benefit immensely from them. Table 5 lists several that EDs should have to provide basic dental care until definitive care from a dental professional can be provided. The Dental Box (www.dentalbox.net, 412-364-8712) is one commercially available dental kit designed for the emergency department. Also available is Dr.

Stahl's Emergency Dental Kit (www.apohealth.com, 1-800-365-2839), which is designed for home use. Other dental supply companies that supply these medications and materials include www.pattersondental.com, www.henryschein.com, and www.smartpractice.com. Many of these items can also be obtained from local dental suppliers.

Disposition

The vast majority of patients presenting to the ED with dental complaints can be treated as outpatients. Fractured, luxated, and carious teeth as well as simple abscesses can all be followed up as outpatients. The management of fractured teeth should be discussed with a dentist or oral surgeon prior to discharge if possible, especially if there is pulpal or deep dentinal involvement. Likewise, intruded teeth and alveolar ridge fractures require repair within 24 hours, and early consultation is helpful. Remember that most dental visits are precipitated by pain. Treat pain aggressively with oral analgesics and, when necessary, dental blocks.

Deep space infections can be life-threatening and may appear deceptively innocuous early in their course. Generally, if the abscess is limited to the buccal space and cheek area and there is no airway involvement, the patient can be treated as an outpatient. Likewise, if there is only slight swelling unilaterally below the body of the mandible, but the airway and voice are normal, the patient can usually be seen the next day. CT scanning should be obtained, however, if the diagnosis is uncertain or the patient has significant swelling or trismus or if the infection appears to cross the midline. In mild infections, it is prudent to begin antibiotic therapy in the ED and arrange for definitive follow-up the next day. Any patient with airway difficulty, bilateral involvement of the neck, toxic appearance, or a high likelihood of noncompliance should be admitted to the hospital. Borderline cases should be treated with IV antibiotics and asked to return in 24 hours for a recheck if they

Table 5. Dental Equipment Needed In The ED.

- Packing gauze
- Dental roll gauze
- Calcium hydroxide paste *or* glass ionomer cement *or* zinc oxide cement
- Dry Socket Paste *or* eugenol
- Topical anesthetic gel (20% benzocaine or 5% lidocaine)
- Topical bactericidal intraoral solution (Ora-5)
- Periodontal paste (Coe-Pak) *or* self-cure composite
- Bupivacaine cartridges with epinephrine
- EMT Toothsaver™ Preservation System *or* fresh milk
- Zinc oxide/eugenol temporary cement (Temrex)
- Ringed injection syringe
- Stainless steel spatula and mixing pads
- Oral surgery tray with arch bars and ligature wires
- Tongue blades and cotton-tipped applicators
- Disposable electrocautery (*optional*)

cannot follow up with the dentist.

Conclusion

Dental emergencies presenting to the ED are only occasionally life-threatening. However, they are often very painful and frequently of great cosmetic concern to the patient. While many of these patients require definitive care by dentists or oral surgeons, the emergency physician plays an important role in their care. The emergency physician must have a basic working knowledge of the dental anatomy and be prepared to save a tooth, repair soft tissue, treat severe infection, and relieve pain. The medications, glues, pastes, and medicaments will improve over time. ED personnel should feel free to discuss these advances with their dental colleagues. Likewise, the treatment of any dental or maxillofacial emergency should involve specialty consultation when it is beyond the scope of emergency practice. ▲

References

Evidence-based medicine requires a critical appraisal of the literature based upon study methodology and number of subjects. Not all references are equally robust. The findings of a large, prospective, randomized, and blinded trial should carry more weight than a case report.

To help the reader judge the strength of each reference, pertinent information about the study, such as the type of study and the number of patients in the study, will be included in bold type following the reference, where available. In addition, the most informative references cited in the paper, as determined by the authors, will be noted by an asterisk (*) next to the number of the reference.

1. Waldrop RD, Ho B, Reed S. Increasing frequency of dental patients in the urban ED. *Am J Emerg Med* 2000 Oct;18(6):687-689. **(Retrospective chart review; 3943 patients)**
- 2.* Bringham C, Herr RD, Aldous JA. Oral trauma in the emergency department. *Am J Emerg Med* 1993 Sep;11(5):486-490. **(Review)**
3. Dale RA. Dentoalveolar trauma. *Emerg Med Clin North Am* 2000 Aug;18(3):521-538. **(Review)**
- 4.* Klokkevold P. Common dental emergencies. Evaluation and management for emergency physicians. *Emerg Med Clin North Am* 1989 Feb;7(1):29-63. **(Review)**
5. Holmes C, Sutcliffe P. Changes in the characteristics of patients attending an out-of-hours emergency dental service in Edinburgh. *Community Dent Health* 1993 Mar;10(1):65-71. **(Questionnaire)**
- 6.* Haraden BM, Zwemer FL Jr. Descending necrotizing mediastinitis: complication of a simple dental infection. *Ann Emerg Med* 1997 May;29(5):683-686. **(Case report)**
7. Barrett EJ, Kenny DJ. Avulsed permanent teeth: a review of the literature and treatment guidelines. *Endod Dent Traumatol* 1997 Aug;13(4):153-163. **(Review)**
- 8.* Krasner P. Modern treatment of avulsed teeth by emergency physicians. *Am J Emerg Med* 1994 Mar;12(2):241-246. **(Review)**
9. Marino TG, West LA, Liewehr FR, et al. Determination of periodontal ligament cell viability in long shelf-life milk. *J Endod* 2000 Dec;26(12):699-702. **(Prospective, basic science)**
10. King R. Orofacial. In: Montgomery M, Redding S, eds. *Oral-Facial Emergencies—Diagnosis and Management*. 1st ed. Portland: JBK Publishing; 1994. **(Textbook)**
11. Dajani AS, Taubert KA, Wilson W, et al. Prevention of bacterial endocarditis. Recommendations by the American Heart Association. *JAMA* 1997 Jun 11;277(22):1794-1801. **(Consensus development conference, practice guideline, review)**
12. Alonso LL, Purcell TB. Accuracy of the tongue blade test in patients with suspected mandibular fracture. *J Emerg Med* 1995 May-Jun;13(3):297-304. **(Prospective; 110 patients)**
13. Druelinger L, Guenther M, Marchand EG. Radiographic evaluation of the facial complex. *Emerg Med Clin North Am* 2000 Aug;18(3):393-410. **(Review)**
14. Humphreys BF. Otolaryngologic emergencies. *Emerg Med Clin North Am* 1986 Aug;4(3):605-615. **(Review)**
15. Noyek AM, Kassel EE, Wortzman G, et al. Contemporary radiologic evaluation in maxillofacial trauma. *Otolaryngol Clin North Am* 1983 Aug;16(3):473-508. **(Review)**
16. Markowitz BL, Sinow JD, Kawamoto HK Jr, et al. Prospective comparison of axial computed tomography and standard and panoramic radiographs in the diagnosis of mandibular fractures. *Ann Plast Surg* 1999 Feb;42(2):163-169. **(Prospective; 33 mandibular fractures in 21 consecutive patients)**
17. Roberts J, Hedges J, eds. *Clinical Procedures in Emergency Medicine*. 2nd ed. Philadelphia: W.B. Saunders & Co.; 1991. **(Textbook)**
18. Jastak T, Yagiela J, Donaldson D, eds. *Local Anesthesia of the Oral Cavity*. Philadelphia: W.B. Saunders & Co.; 1995. **(Textbook)**
19. Rauschenberger CR, Hovland EJ. Clinical management of crown fractures. *Dent Clin North Am* 1995 Jan;39(1):25-51. **(Review)**
- 20.* Ellis SG. Incomplete tooth fracture—proposal for a new definition. *Br Dent J* 2001 Apr 28;190(8):424-428. **(Review)**
21. Beaudreau R. Oral and dental emergencies. In: Tintinalli JE, Kelen GD, Stapczynski JS, eds. *Emergency Medicine—A Comprehensive Study Guide*. 5th ed. New York: McGraw-Hill; 2000. **(Textbook)**
22. Bakland LK, Milledge T, Nation W. Treatment of crown fractures. *J Calif Dent Assoc* 1996 Feb;24(2):45-50. **(Review)**
23. Amsterdam J. Dental disorders. In: Rosen P, Barkin R, eds. *Emergency Medicine: Concepts and Clinical Practice*. 4th ed. St. Louis: Mosby; 1998. **(Textbook)**
24. Blatz MB. Comprehensive treatment of traumatic fracture and luxation injuries in the anterior permanent dentition. *Pract Proced Aesthet Dent* 2001 May;13(4):273-279. **(Review)**
25. Gilbert DN, et al, eds. *The Sanford Guide to Antimicrobial Therapy*. Hyde Park, VT: Antimicrobial Therapy, Inc.; 2002. **(Textbook)**
26. Dumsha TC. Luxation injuries. *Dent Clin North Am* 1995 Jan;39(1):79-91. **(Review)**
27. Olson BD, Mailhot JM, Anderson RW, et al. Comparison of various transport media on human periodontal ligament cell viability. *J Endod* 1997 Nov;23(11):676-679. **(Comparative, basic science)**
28. Lee JY, Vann WF Jr, Sigurdsson A. Management of avulsed permanent incisors: a decision analysis based on changing concepts. *Pediatr Dent* 2001 Jul-Aug;23(4):357-360. **(Review)**
29. Steele MT, Sainsbury CR, Robinson WA, et al. Prophylactic penicillin for intraoral wounds. *Ann Emerg Med* 1989 Aug;18(8):847-852. **(Randomized, controlled trial; 62 patients)**
30. Trott A. *Wounds and Lacerations*. 2nd ed. New York: Mosby; 1997. **(Textbook)**
31. McQuone S. Neck emergencies. In: Eisele D, McQuone S. *Emergencies of the Head and Neck*. 1st ed. St. Louis: Mosby; 2000. **(Textbook)**
32. Loesche WJ. Dental infections. In: Gorbach SL, Bartlett JG, Blacklow NR, eds. *Infectious Diseases*. 2nd ed. Philadelphia: W.B. Saunders; 1998:499-508. **(Textbook)**
33. Herrera D, Roldan S, Sanz M. The periodontal abscess: a review. *J Clin Periodontol* 2000 Jun;27(6):377-386. **(Review)**
34. Ashman S. Oral cavity and dental emergencies. In: Eisele DW, McQuone SJ, eds. *Emergencies of the Head and Neck*. St. Louis: Mosby; 2000. **(Textbook)**
35. Flynn TR. The swollen face. Severe odontogenic infections. *Emerg Med Clin North Am* 2000 Aug;18(3):481-519. **(Review)**
36. Lazor JB, Cunningham MJ, Eavey RD, et al. Comparison of computed tomography and surgical findings in deep neck infections. *Otolaryngol Head Neck Surg* 1994 Dec;111(6):746-750.

(Retrospective; 38 patients)

37. Neff SP, Merry AF, Anderson B. Airway management in Ludwig's angina. *Anaesth Intensive Care* 1999 Dec;27(6):659-661. (Case report)
- 38.* Shockley WW. Ludwig angina: a review of current airway management. *Arch Otolaryngol Head Neck Surg* 1999 May;125(5):600. (Review)

Physician CME Questions

65. Which of the following about adult dentition is correct?
- There are eight incisors, four canines, eight premolars, and 12 molars.
 - There are four incisors, four canines, 12 premolars, and 12 molars.
 - There are six incisors, four canines, 10 premolars, and 12 molars.
 - None of the above.
66. Of the following dental emergencies, which requires the *least urgent* intervention?
- Trauma that could potentially cause airway compromise
 - Mucosal or tongue lacerations
 - Deep space infections
 - Uncomplicated tooth pain
67. Avulsed teeth should be rinsed and wiped off prior to reimplantation.
- True
 - False
68. In obtaining a patient history in the case of dental trauma, which of the following suggest(s) that an avulsed tooth could have been aspirated?
- Coughing after the injury
 - Use of alcohol, sedatives, or recreational drugs
 - Loss of consciousness
 - All of the above
69. Which of the following systemic conditions may cause oral pain or symptoms?
- Cranial neuralgias
 - Stomatitis and mucositis
 - Erythema migrans
 - Crohn's disease
 - All of the above
70. In cases of dental trauma, prehospital care providers should *avoid* all of the following *except*:
- placing the patient in a supine position (unless cervical spine injury is a concern).
 - placing over-the-counter topical anesthetics on the wound.
 - controlling hemorrhages with gauze and direct pressure.
 - transporting an avulsed tooth in the patient's mouth to preserve the periodontal ligament.
71. The use of ringed syringe aspirators is recommended for intraoral injections.
- True
 - False
72. The inability to crack a tongue blade bilaterally when it is twisted between the molars suggests:
- a mandibular fracture.
 - a deep space infection.
 - gingivitis.
 - temporomandibular joint disorder.
73. The quickest way to relieve severe odontalgia in the ED is with:
- NSAIDs.
 - narcotic pain medication.
 - dental block.
 - none of the above.
74. Which of the following affect successful reimplantation after a tooth has been completely knocked out of the socket?
- Duration of time the tooth has been out
 - Type of solution or medium that the tooth has been kept in
 - The health of the surrounding periodontium
 - All of the above
75. Which of the following is the best choice for a dental block for a condition for which the patient will be treated by a dentist the next day?
- Mepivacaine with levonordefrin
 - Bupivacaine with epinephrine
 - Mepivacaine
 - Prilocaine with epinephrine
76. The most commonly fractured teeth are:
- the molars.
 - the canines.
 - the maxillary central incisors.
 - the premolars.
77. All of the following are true about complicated fractures of the crown that extend into the pulp of the tooth *except*:
- They are also known as Ellis class III fractures.
 - They do not need to be handled urgently.
 - They result in pulp necrosis in 10%-30% of cases, even with appropriate treatment.
 - They are distinguished from fractures of the dentin by the pink color of the pulp.
78. All of the following are true about intraoral lacerations *except*:
- They almost always become infected, so prophylactic antibiotics are recommended by most specialty societies.
 - If there is a significant amount of devitalized or crushed tissue present, coverage of oral flora (penicillin or clindamycin) may be considered.
 - If the wound is through-and-through, coverage of oral flora (penicillin or clindamycin) and additional skin coverage (clindamycin or dicloxacillin) may be considered.
 - Most tongue lacerations that are less than a centimeter and whose wound edges are not gaping do not require repair.

79. Avulsed primary teeth:

- a. should be replaced only if it can be done within 30 minutes.
- b. should be replaced only if the child is younger than 6 years.
- c. should be replaced only if the root has been preserved adequately.
- d. should not be replaced, because they could cause craniofacial abnormalities, infection, or interfere with normal eruption of the permanent teeth.

80. Treatment of alveolar bone fractures requires rigid splinting of the affected segment by an oral surgeon or dentist as soon as possible.

- a. True
- b. False

Class Of Evidence Definitions

Each action in the clinical pathways section of *Emergency Medicine Practice* receives an alpha-numerical score based on the following definitions.

Class I

- Always acceptable, safe
- Definitely useful
- Proven in both efficacy and effectiveness

Level of Evidence:

- One or more large prospective studies are present (with rare exceptions)
- High-quality meta-analyses
- Study results consistently positive and compelling

Class II

- Safe, acceptable
- Probably useful

Level of Evidence:

- Generally higher levels of evidence
- Non-randomized or retrospective studies: historic, cohort, or case-control studies
- Less robust RCTs
- Results consistently positive

Class III

- May be acceptable
- Possibly useful
- Considered optional or alternative treatments

Level of Evidence:

- Generally lower or intermediate levels of evidence

- Case series, animal studies, consensus panels
- Occasionally positive results

Indeterminate

- Continuing area of research
- No recommendations until further research

Level of Evidence:

- Evidence not available
- Higher studies in progress
- Results inconsistent, contradictory
- Results not compelling

Significantly modified from: The Emergency Cardiovascular Care Committees of the American Heart Association and representatives from the resuscitation councils of ILCOR: How to Develop Evidence-Based Guidelines for Emergency Cardiac Care: Quality of Evidence and Classes of Recommendations; also: Anonymous. Guidelines for cardiopulmonary resuscitation and emergency cardiac care. Emergency Cardiac Care Committee and Subcommittees, American Heart Association. Part IX. Ensuring effectiveness of community-wide emergency cardiac care. *JAMA* 1992;268(16):2289-2295.

Physician CME Information

This CME enduring material is sponsored by Mount Sinai School of Medicine and has been planned and implemented in accordance with the Essentials and Standards of the Accreditation Council for Continuing Medical Education. Credit may be obtained by reading each issue and completing the printed post-tests administered in December and June or online single-issue post-tests administered at www.empractice.net.

Target Audience: This enduring material is designed for emergency medicine physicians.

Needs Assessment: The need for this educational activity was determined by a survey of medical staff, including the editorial board of this publication; review of morbidity and mortality data from the CDC, AHA, NCHS, and ACEP; and evaluation of prior activities for emergency physicians.

Date of Original Release: This issue of *Emergency Medicine Practice* was published May 1, 2003. **This activity is eligible for CME credit through May 1, 2006.** The latest review of this material was April 9, 2003.

Discussion of Investigational Information: As part of the newsletter, faculty may be presenting investigational information about pharmaceutical products that is outside Food and Drug Administration approved labeling. Information presented as part of this activity is intended solely as continuing medical education and is not intended to promote off-label use of any pharmaceutical product. *Disclosure of Off-Label Usage:* This issue of *Emergency Medicine Practice* discusses no off-label use of any pharmaceutical product.

Faculty Disclosure: In compliance with all ACCME Essentials, Standards, and Guidelines, all faculty for this CME activity were asked to complete a full disclosure statement. The information received is as follows: Dr. Benko is the proprietor of Dental Box Company. Dr. Burke and Dr. Stewart report no significant financial interest or other relationship with the manufacturer(s) of any commercial product(s) discussed in this educational presentation.

Accreditation: Mount Sinai School of Medicine is accredited by the Accreditation Council for Continuing Medical Education to sponsor continuing medical education for physicians.

Credit Designation: Mount Sinai School of Medicine designates this educational activity for up to 4 hours of Category 1 credit toward the AMA Physician's Recognition Award. Each physician should claim only those hours of credit actually spent in the educational activity. *Emergency Medicine Practice* is approved by the American College of Emergency Physicians for 48 hours of ACEP Category 1 credit (per annual subscription). *Emergency Medicine Practice* has been reviewed and is acceptable for up to 48 Prescribed credit hours by the American Academy of Family Physicians. *Emergency Medicine Practice* has been approved for 48 Category 2-B credit hours by the American Osteopathic Association.

Earning Credit: Two Convenient Methods

- **Print Subscription Semester Program:** Paid subscribers with current and valid licenses in the United States who read all CME articles during each *Emergency Medicine Practice* six-month testing period, complete the post-test and the CME Evaluation Form distributed with the December and June issues, and return it according to the published instructions are eligible for up to 4 hours of Category 1 credit toward the AMA Physician's Recognition Award (PRA) for each issue. You must complete both the post-test and CME Evaluation Form to receive credit. Results will be kept confidential. CME certificates will be delivered to each participant scoring higher than 70%.
- **Online Single-Issue Program:** Paid subscribers with current and valid licenses in the United States who read this *Emergency Medicine Practice* CME article and complete the online post-test and CME Evaluation Form at www.empractice.net are eligible for up to 4 hours of Category 1 credit toward the AMA Physician's Recognition Award (PRA). You must complete both the post-test and CME Evaluation Form to receive credit. Results will be kept confidential. CME certificates may be printed directly from the Web site to each participant scoring higher than 70%.

Emergency Medicine Practice is not affiliated with any pharmaceutical firm or medical device manufacturer.

Publisher: Robert Williford. **Executive Editor:** Heidi Frost.

Direct all editorial or subscription-related questions to EB Practice, LLC: 1-800-249-5770 • Fax: 1-770-500-1316 • Non-U.S. subscribers, call: 1-678-366-7933

EB Practice, LLC • 305 Windlake Court • Alpharetta, GA 30022

E-mail: emp@empractice.net • Web Site: <http://www.empractice.net>

Emergency Medicine Practice (ISSN 1524-1971) is published monthly (12 times per year) by EB Practice, LLC, 305 Windlake Court, Alpharetta, GA 30022. Opinions expressed are not necessarily those of this publication. Mention of products or services does not constitute endorsement. This publication is intended as a general guide and is intended to supplement, rather than substitute, professional judgment. It covers a highly technical and complex subject and should not be used for making specific medical decisions. The materials contained herein are not intended to establish policy, procedure, or standard of care. *Emergency Medicine Practice* is a trademark of EB Practice, LLC. Copyright ©2003 EB Practice, LLC. All rights reserved. No part of this publication may be reproduced in any format without written consent of EB Practice, LLC. Subscription price: \$299, U.S. funds. (Call for international shipping prices.)